

Synovitída kolena po artroskopii pri dekompenzovanej gonartróze 3.stupňa

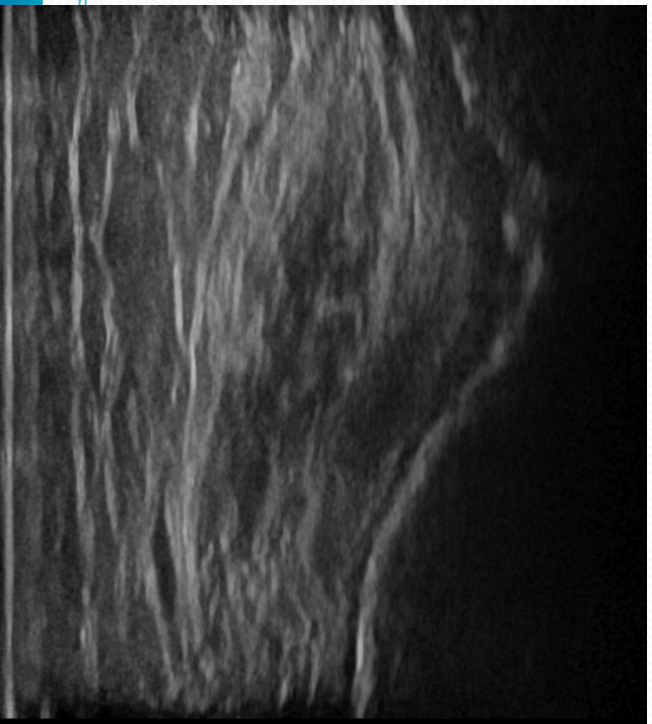
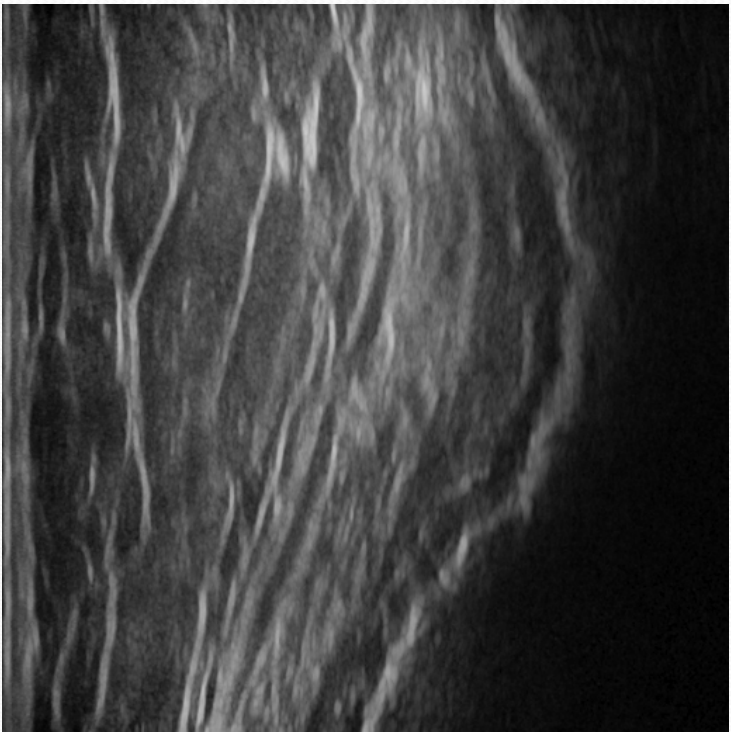
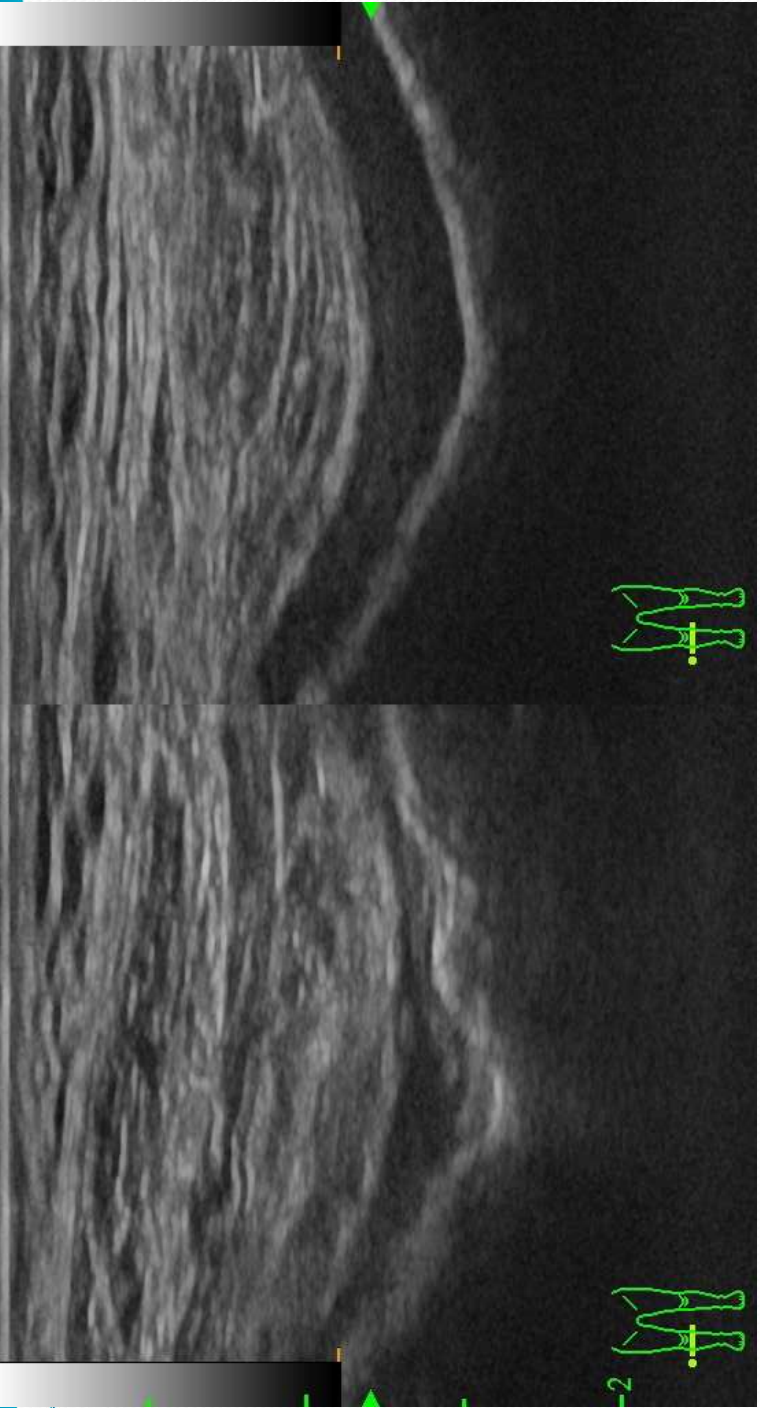
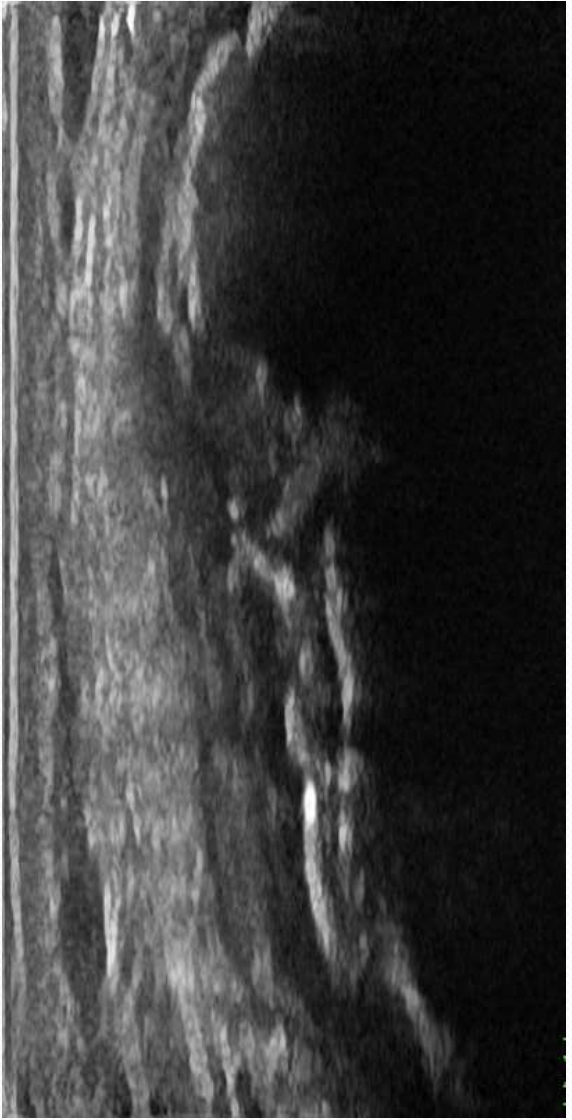MUDr. Jozef Vojtaššák, PhD.
Prof. MUDr. Jozef Vojtaššák, CSc.
Clinica Orthopedica, Bratislava

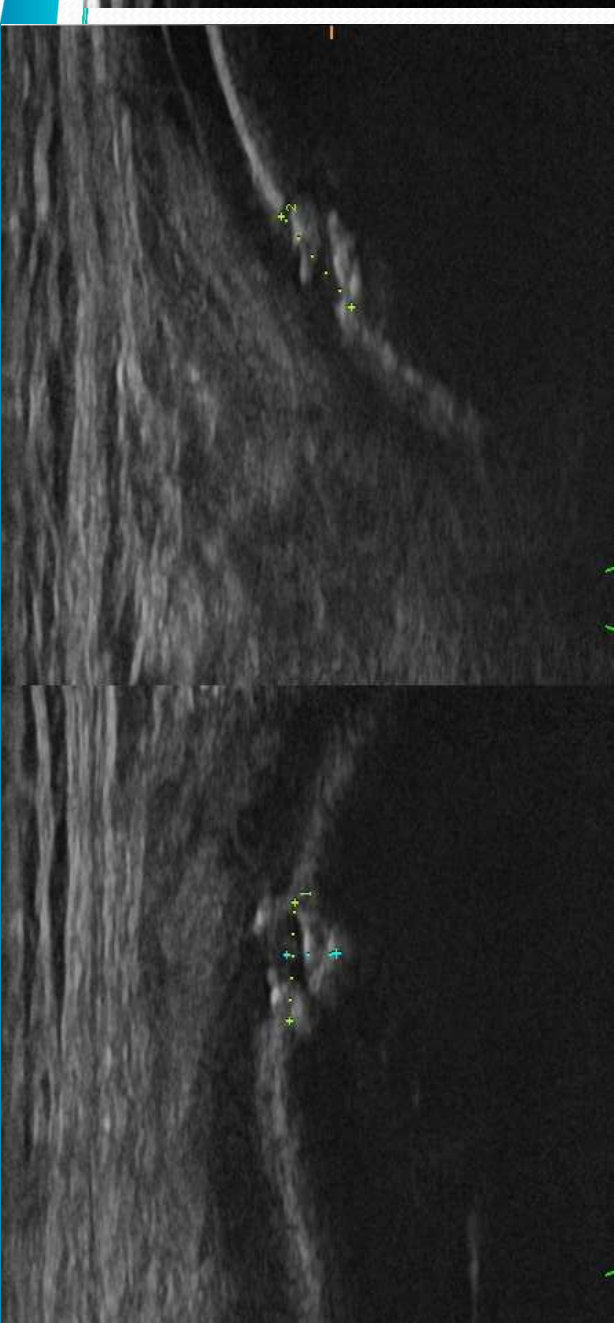
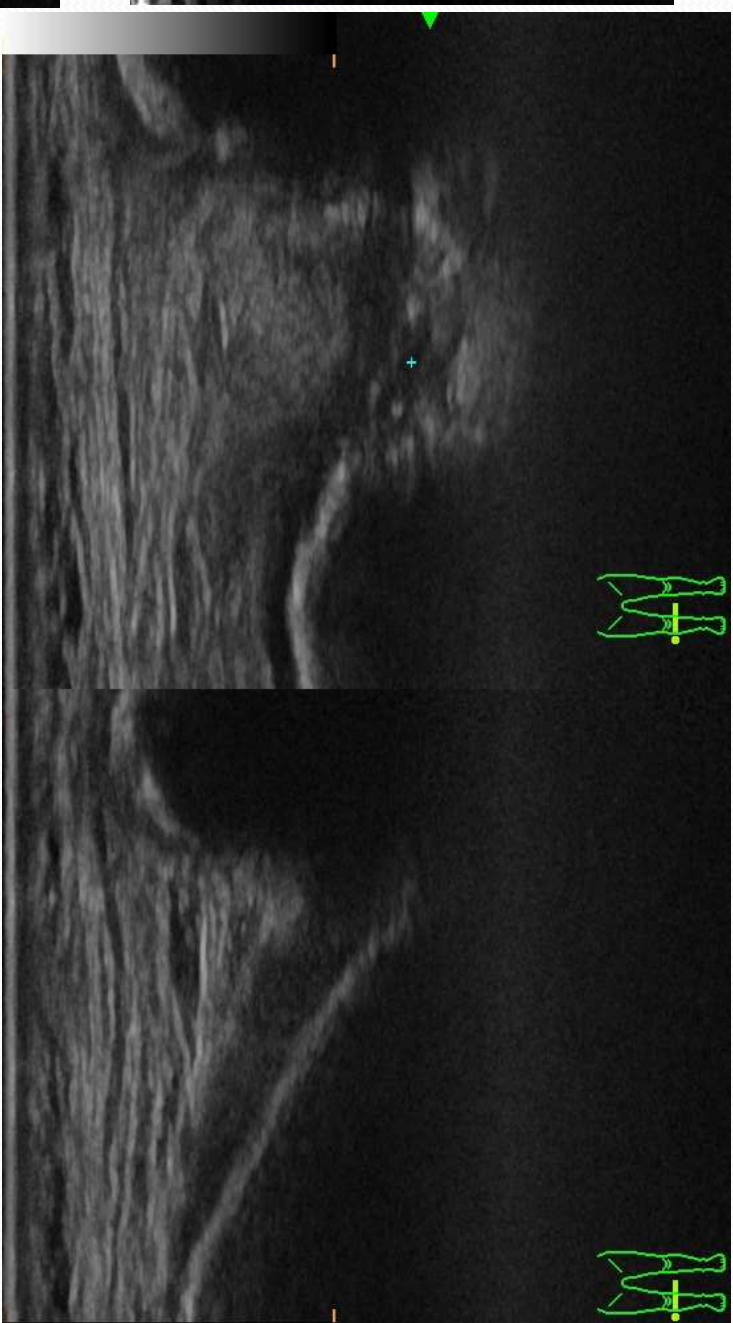
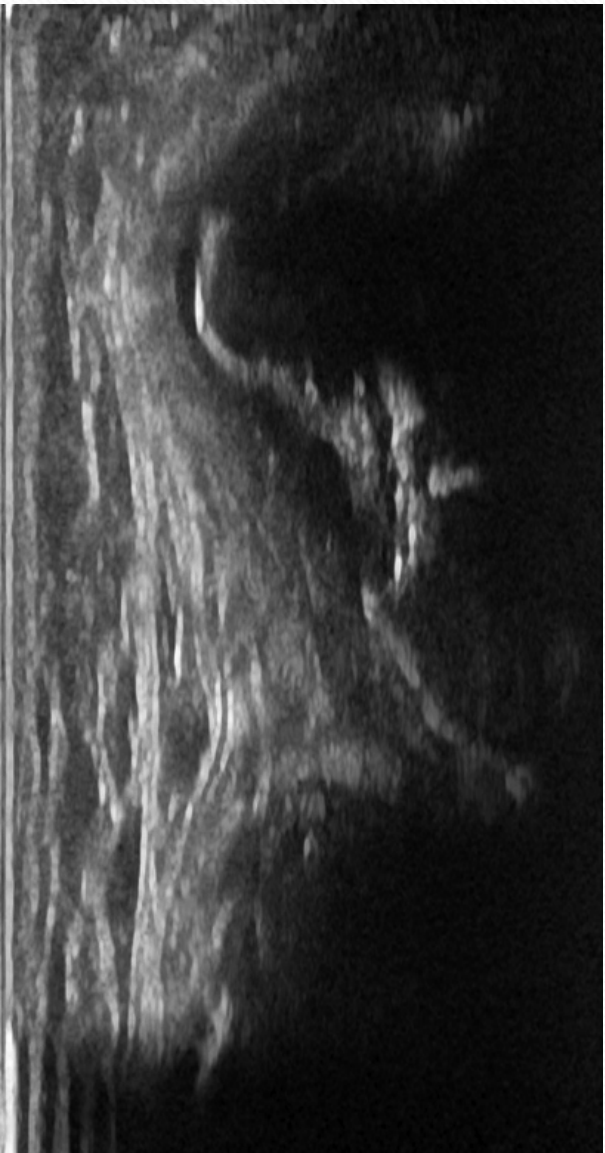
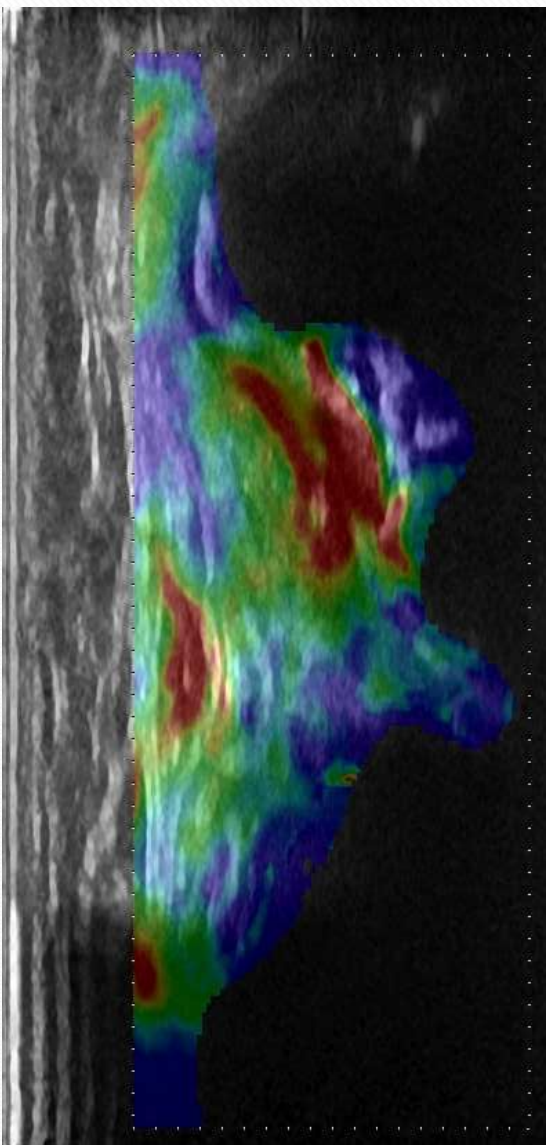
Úvod

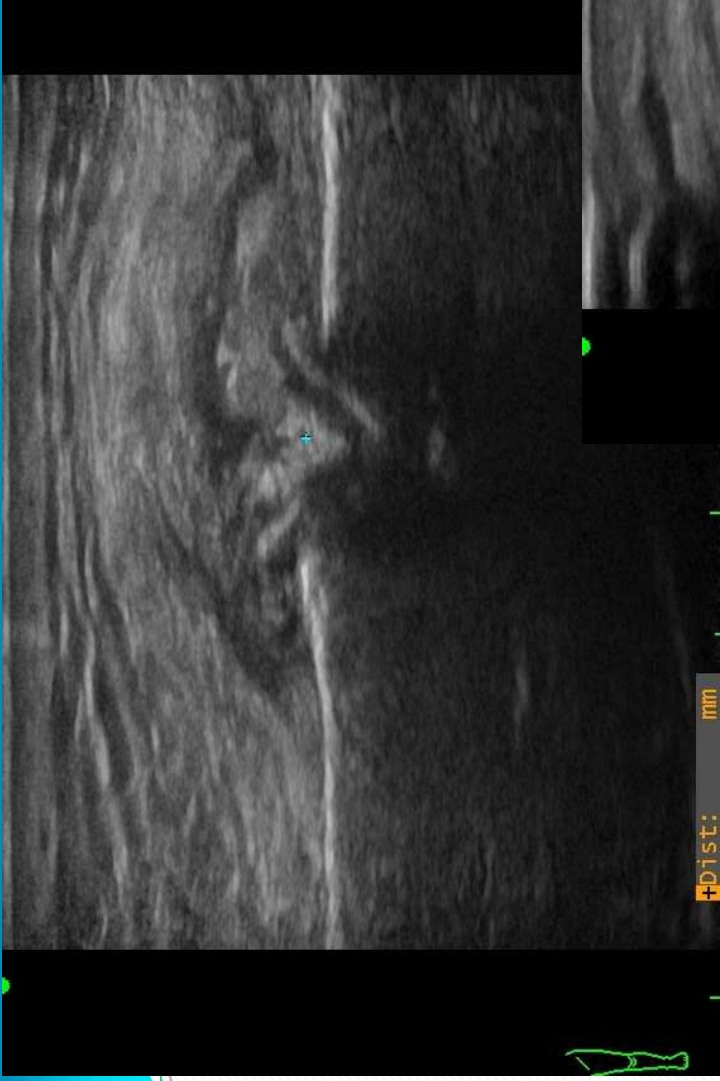
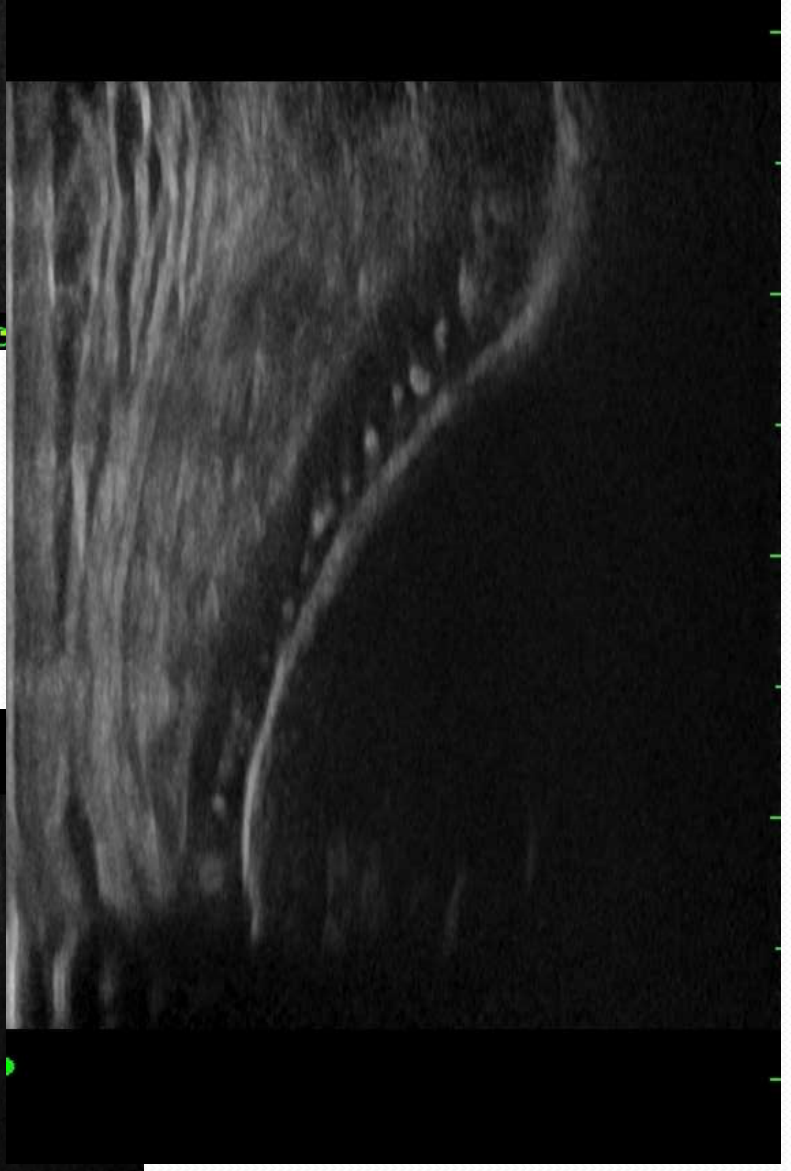
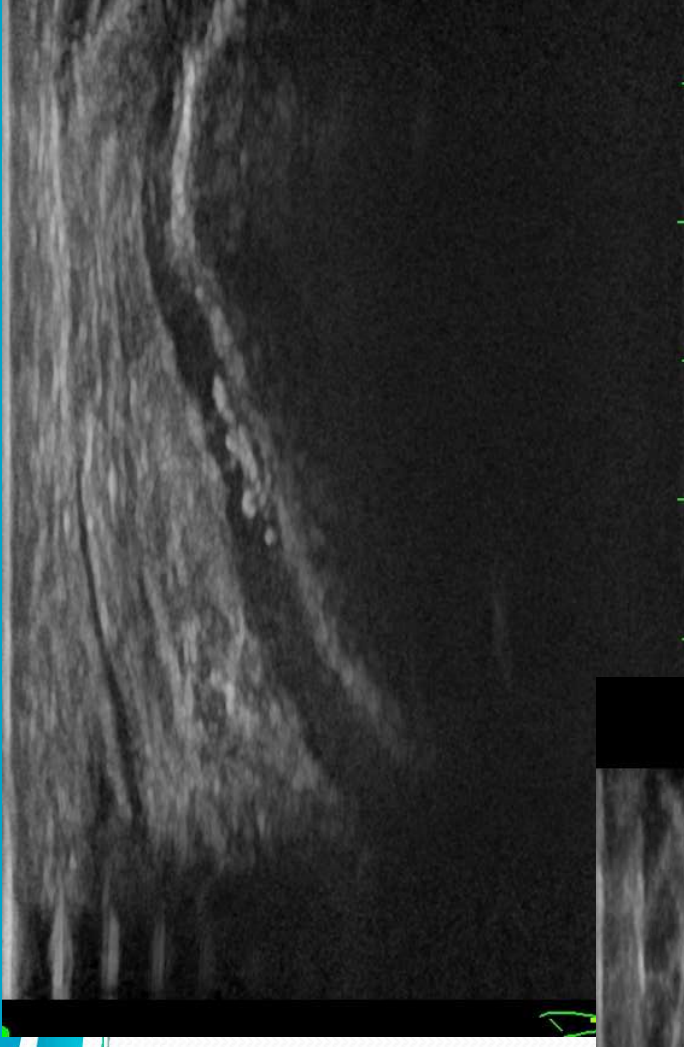- Artroskopický debridement kolena pri artróze
 - symptomatická liečba
 - po vyčerpaní konzervatívnej liečby
 - oddialenia TEP v mladšom veku
 - sporný benefit tejto liečby
 - zvyšujúca tendenciu

Gonartróza

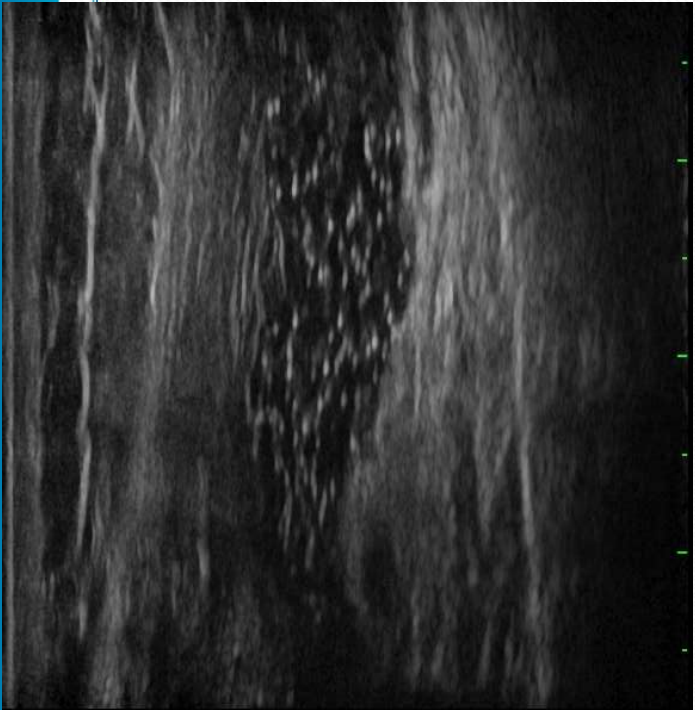
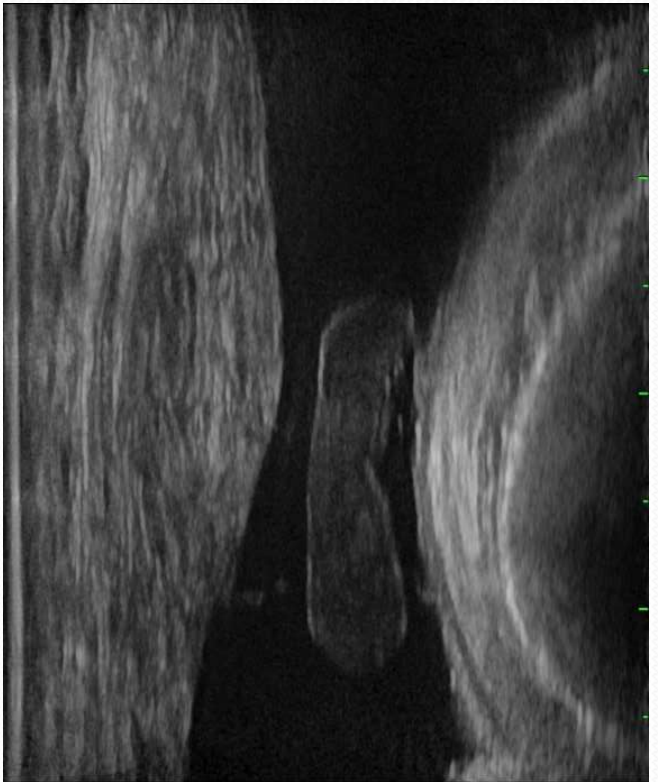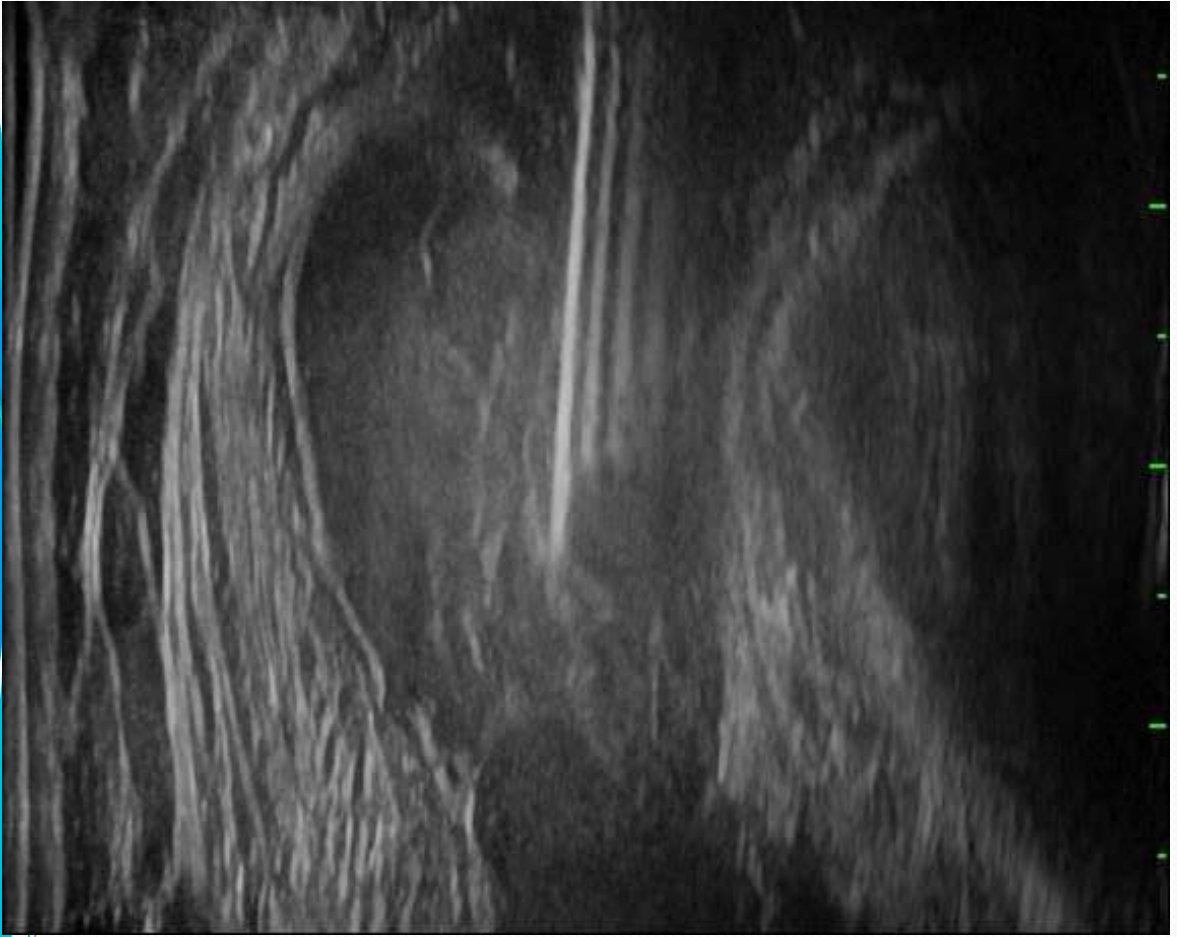- strata jasného ohraničenia povrchovej vrstvy chrupavky
- strata transparentnosti chrupavky
- zníženie hrúbky chrupavky
- iregularita subchondrálnej kosti
- marginálne osteofyty
- subluxácia med. meniskov
- synovitída, náplň, voľné telesá....

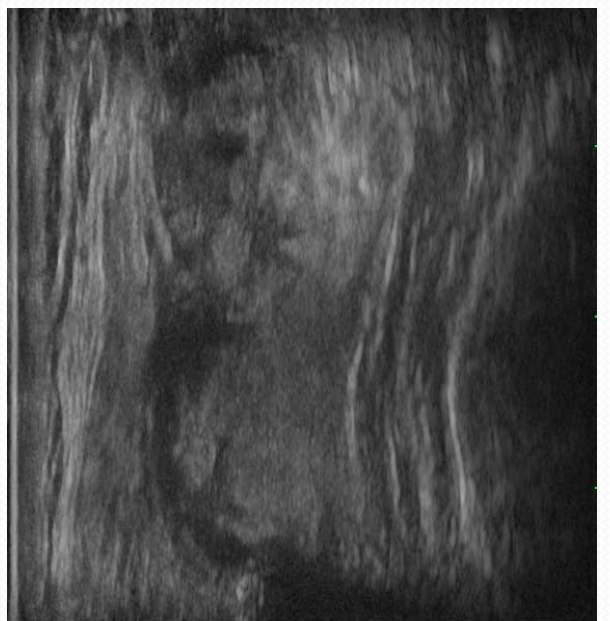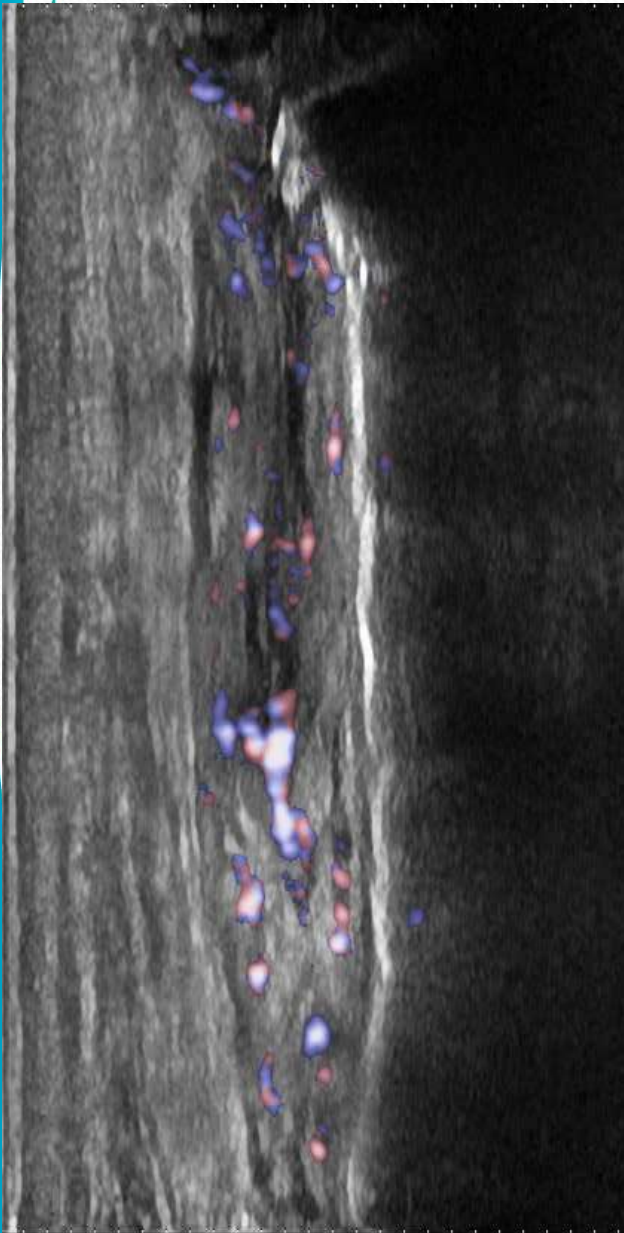
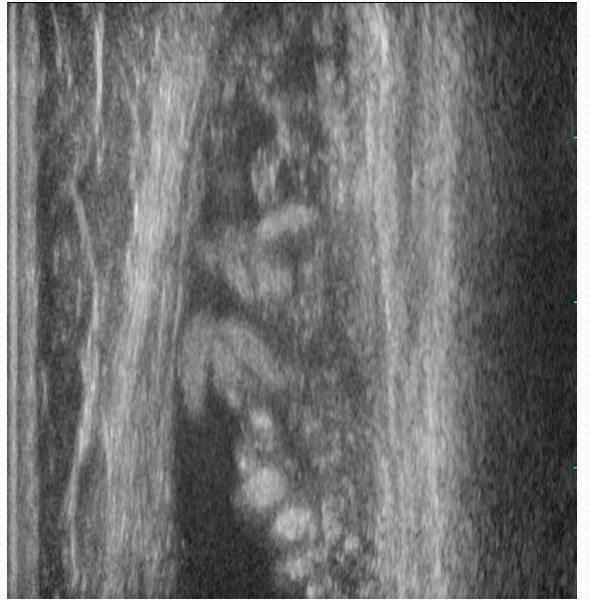
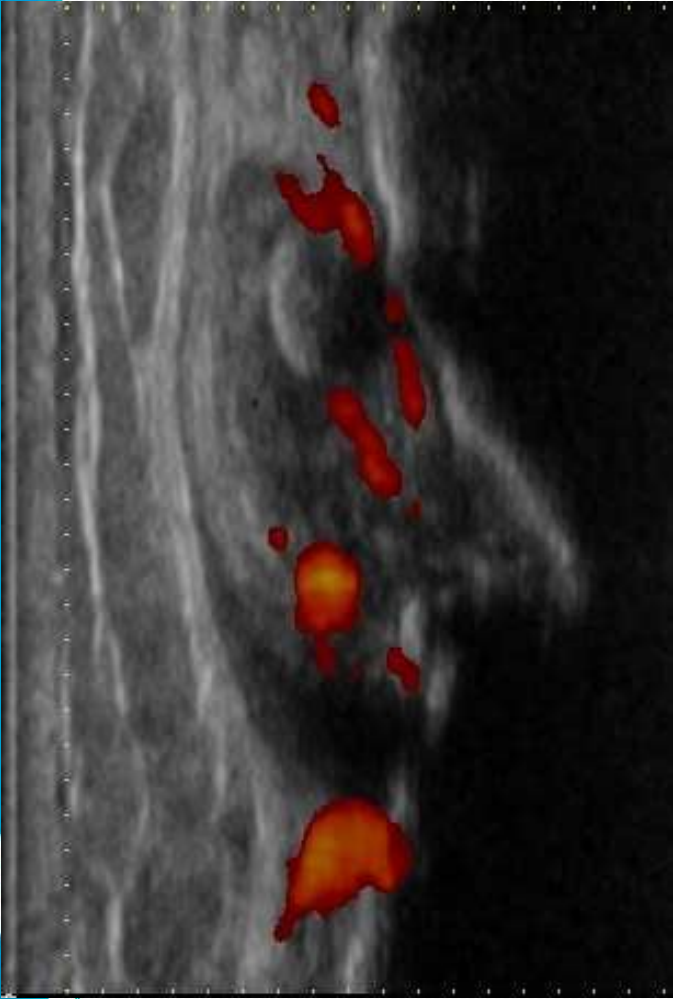


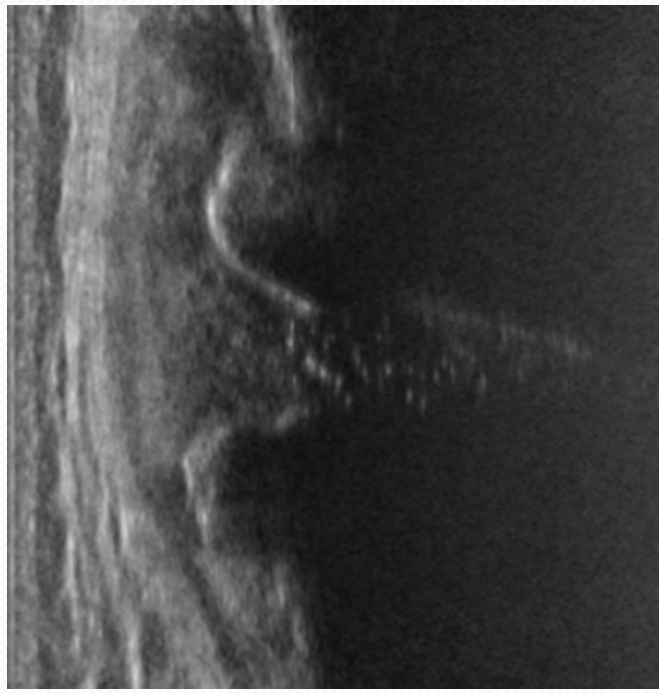
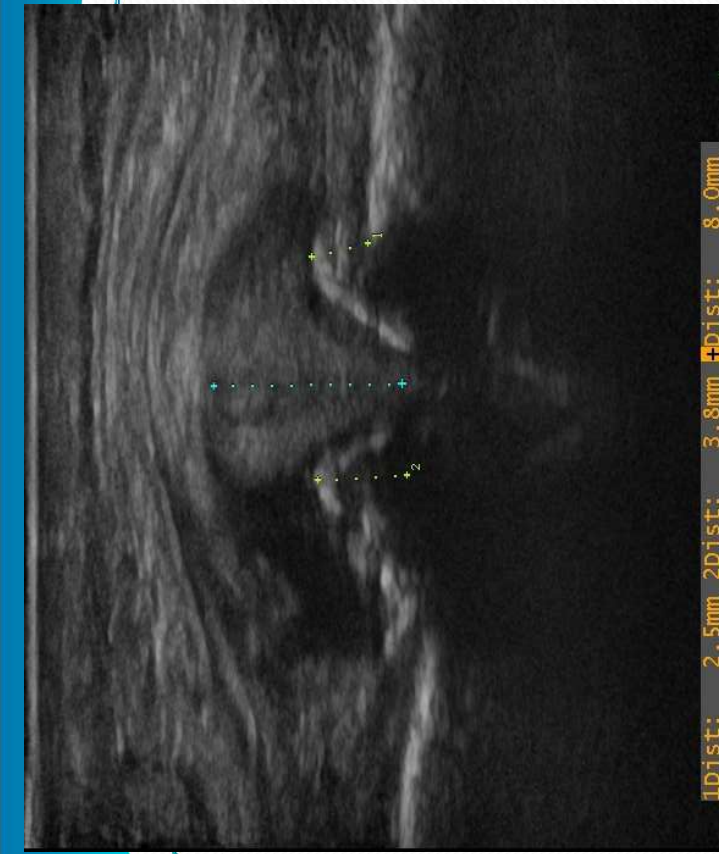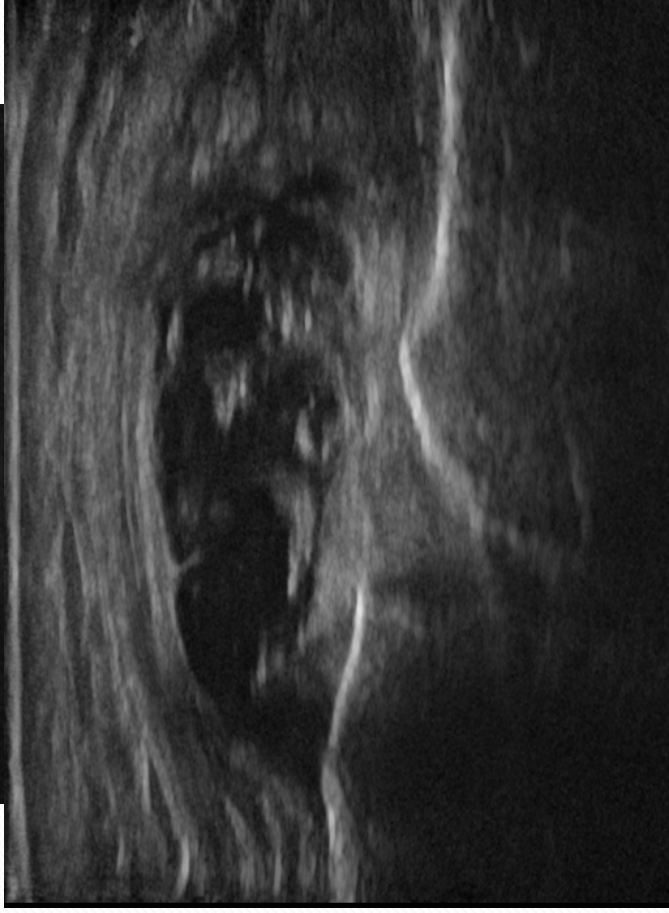
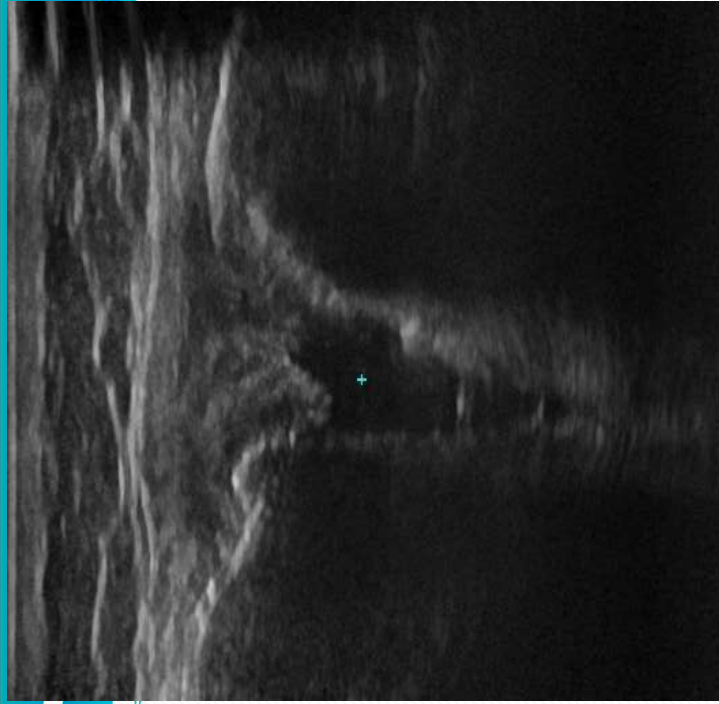


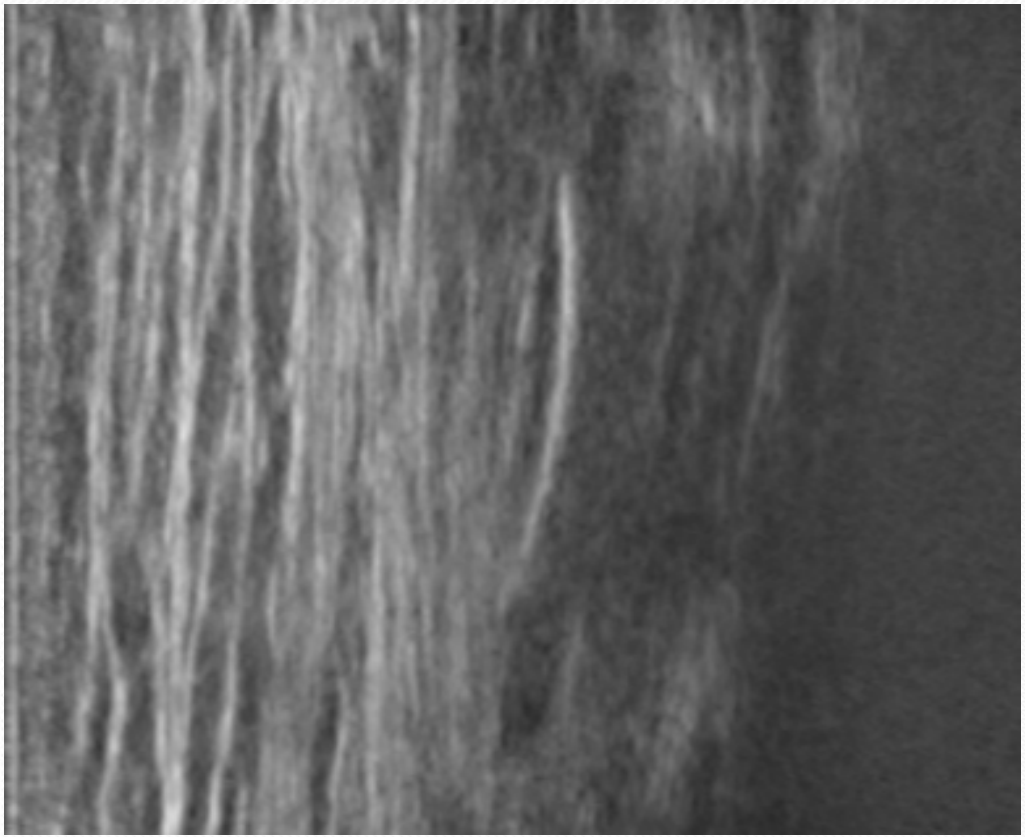
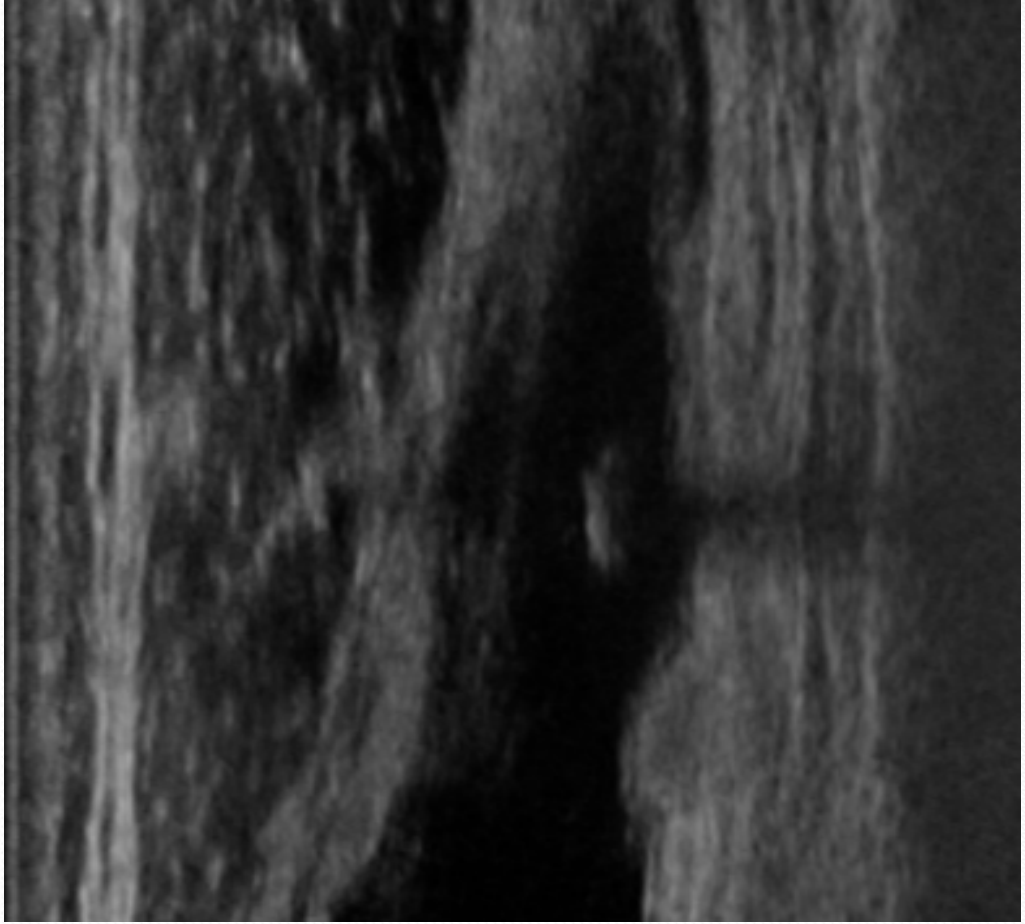


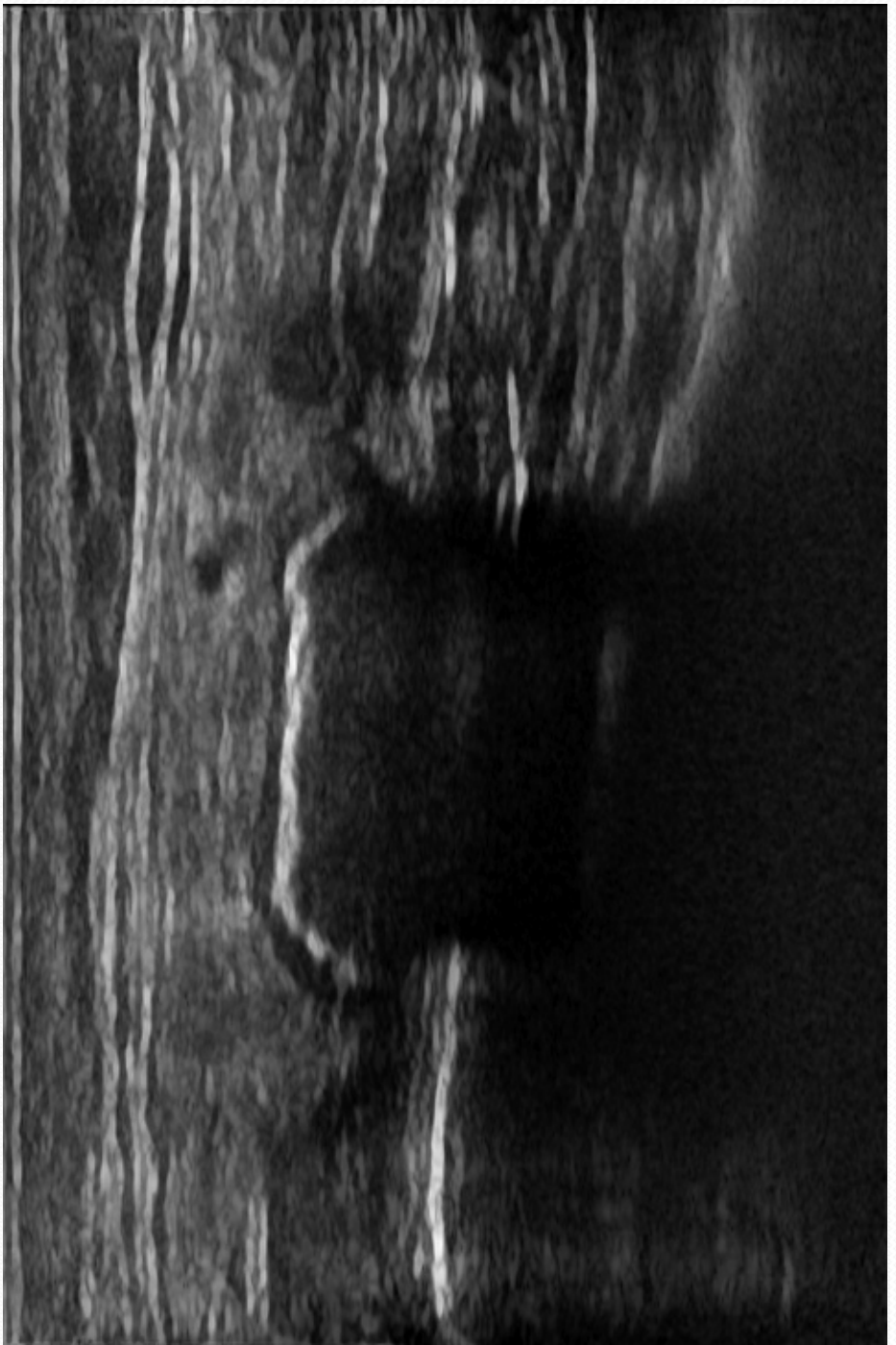
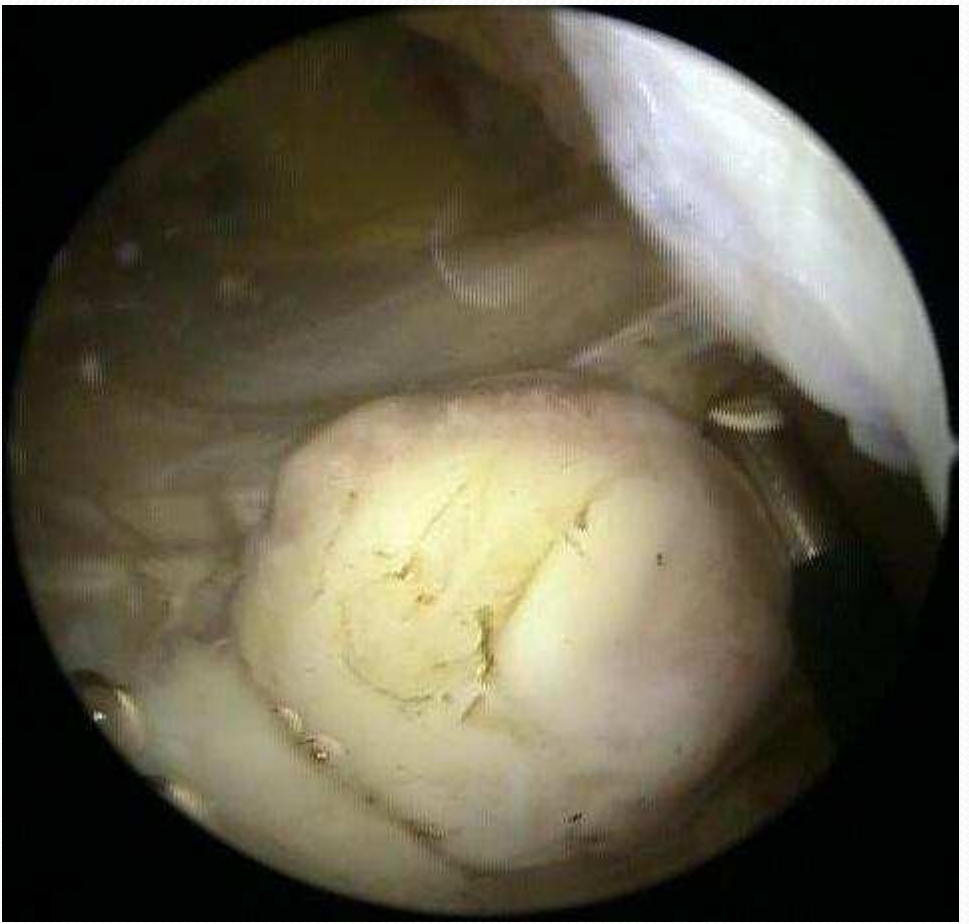Dist: 10 mm

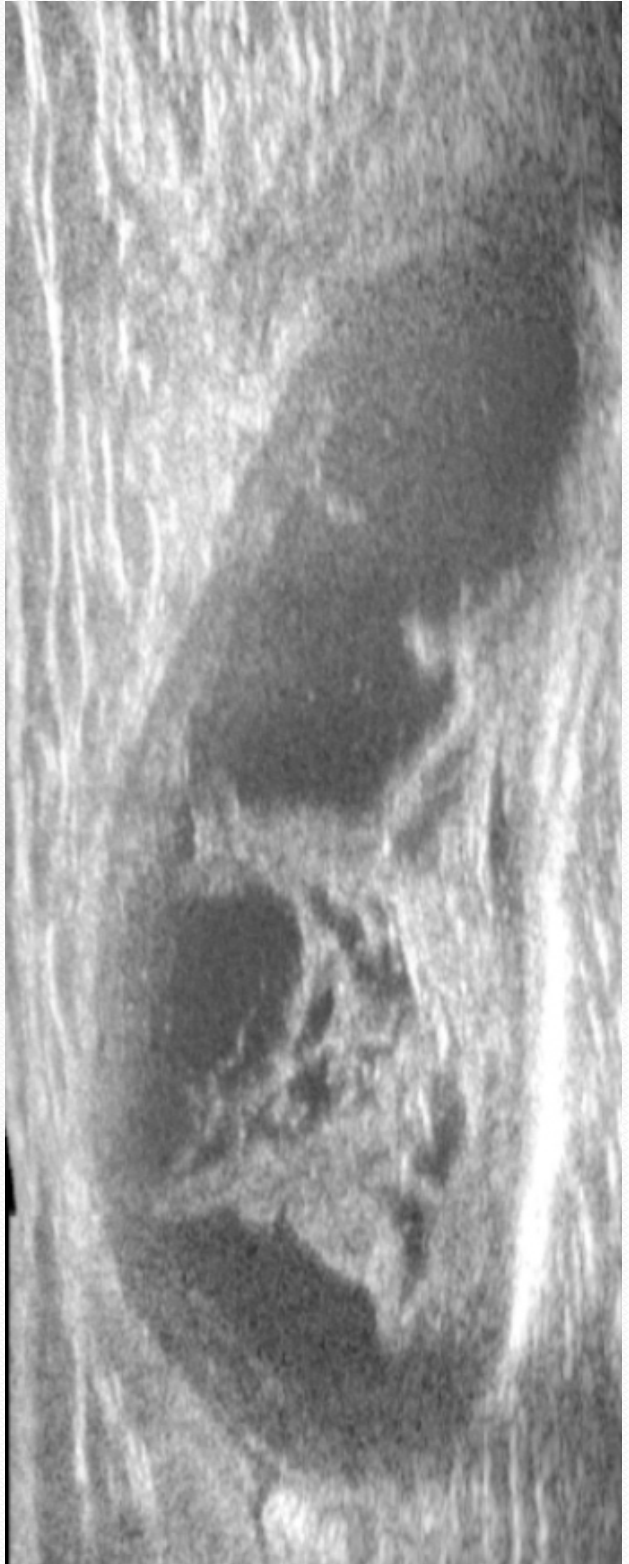
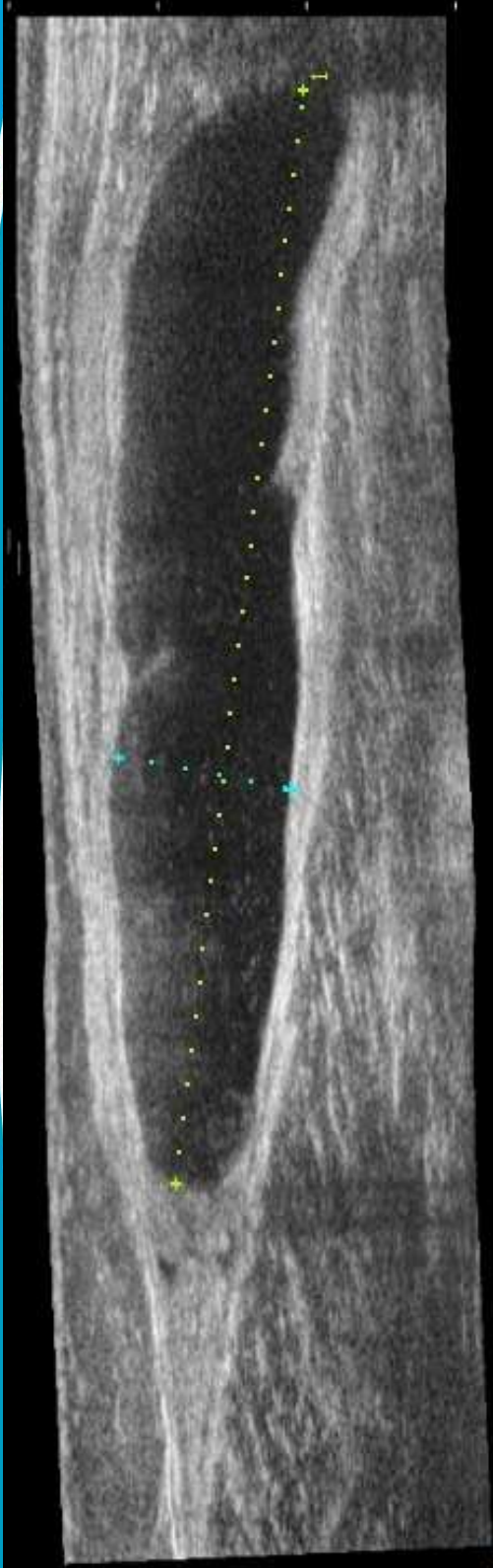
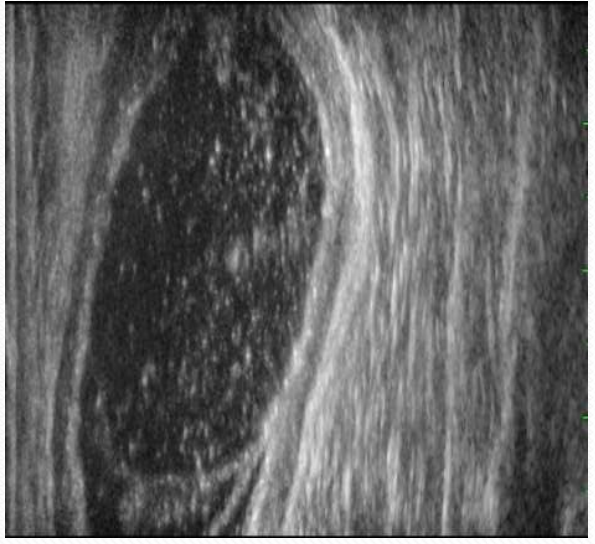
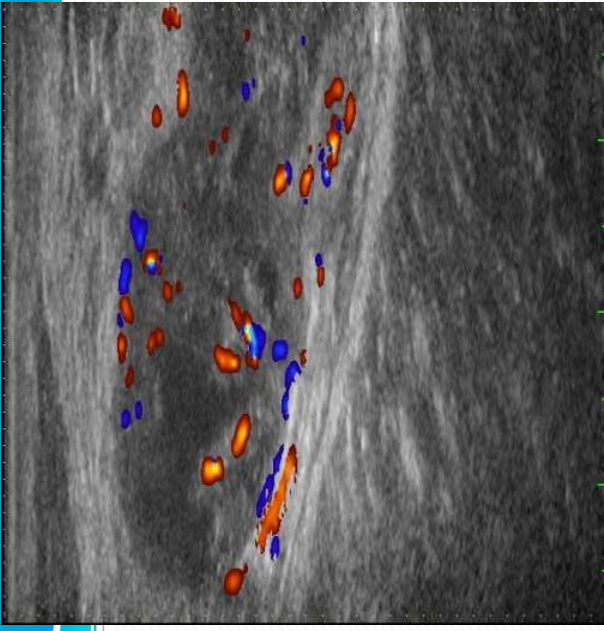


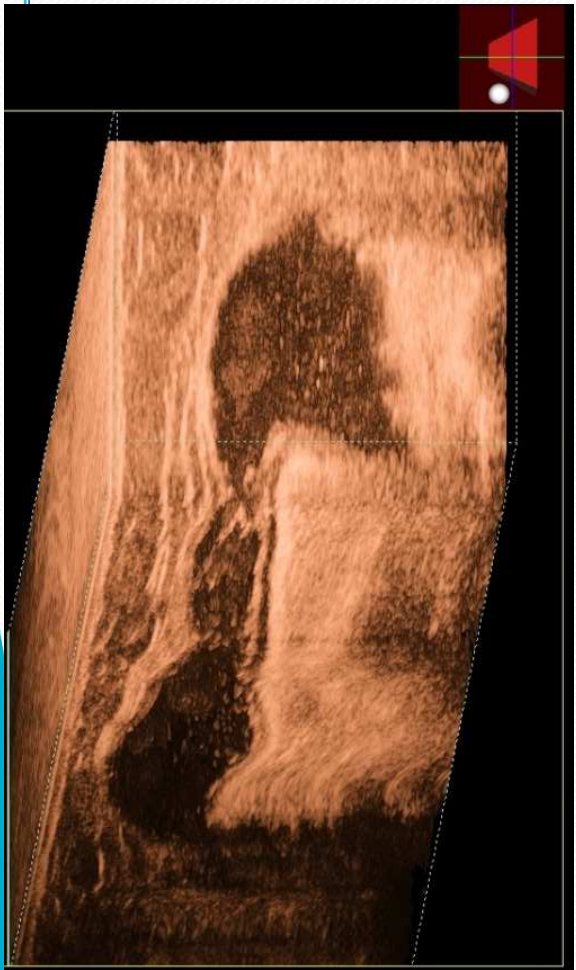
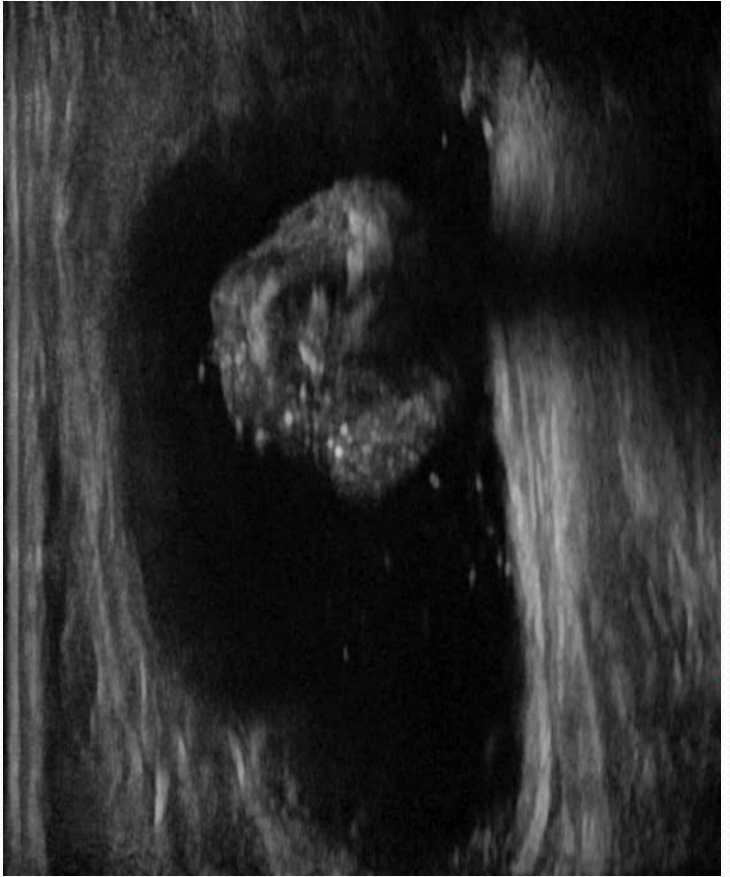
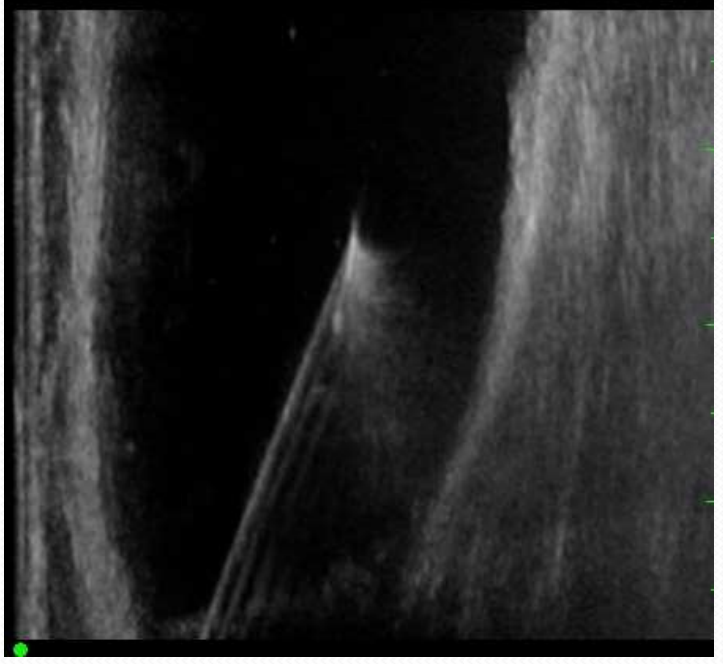
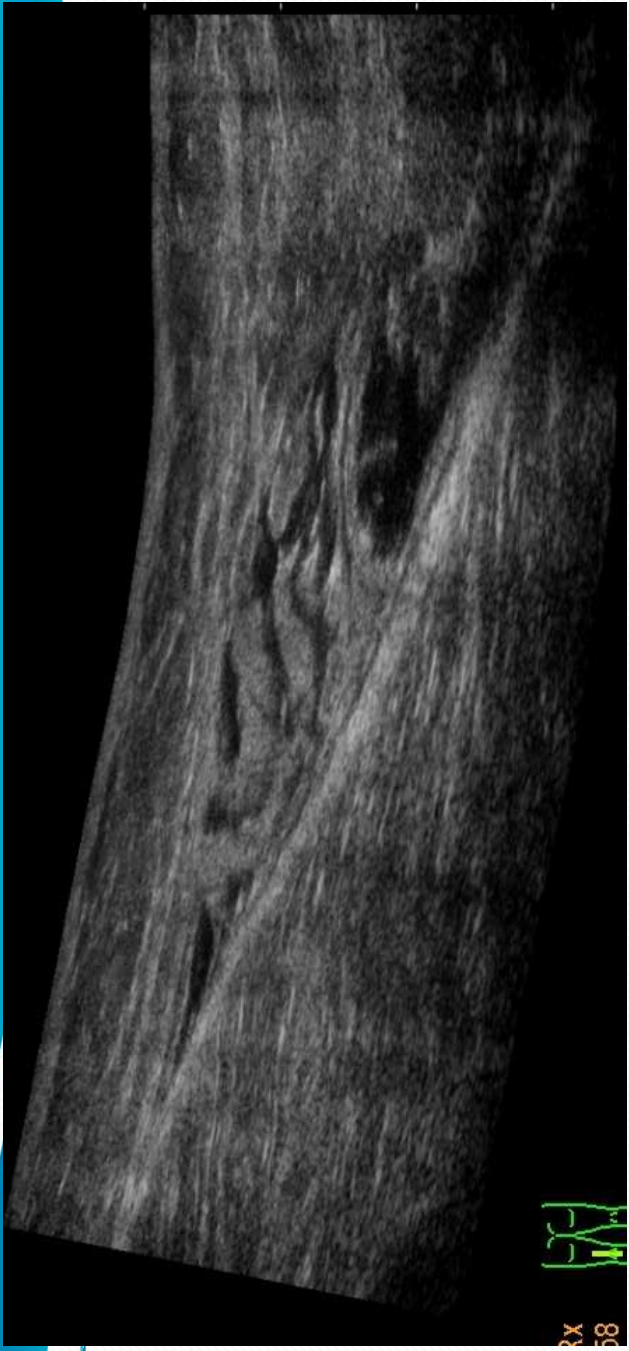




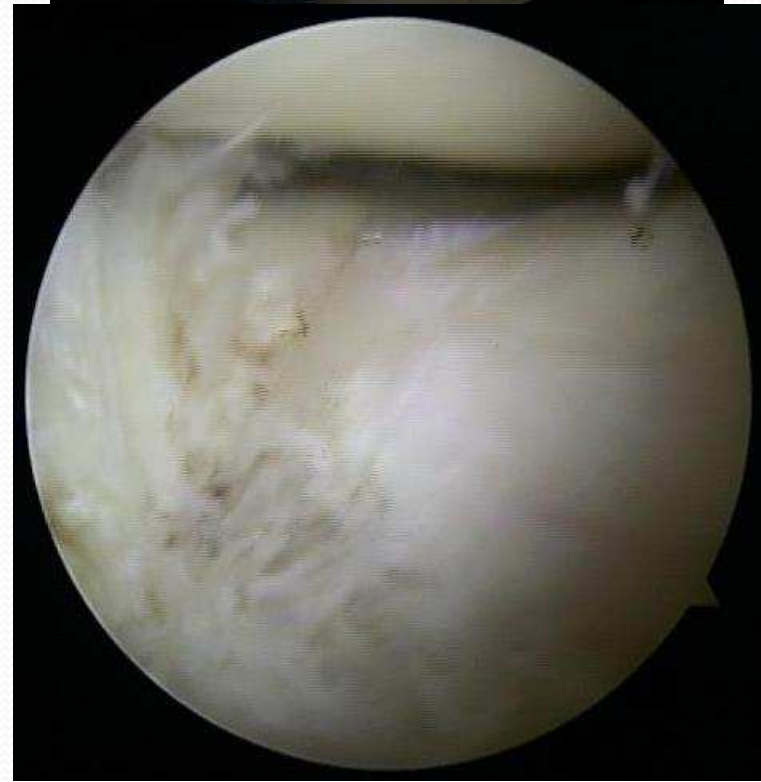
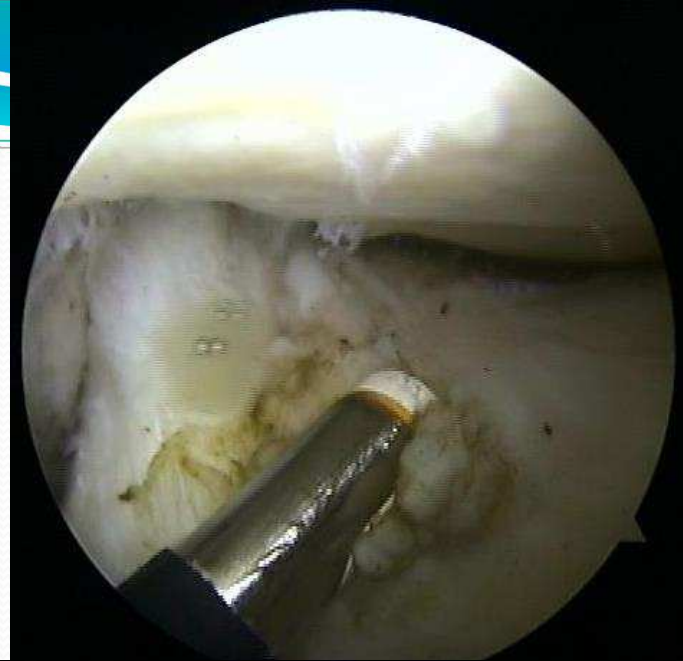
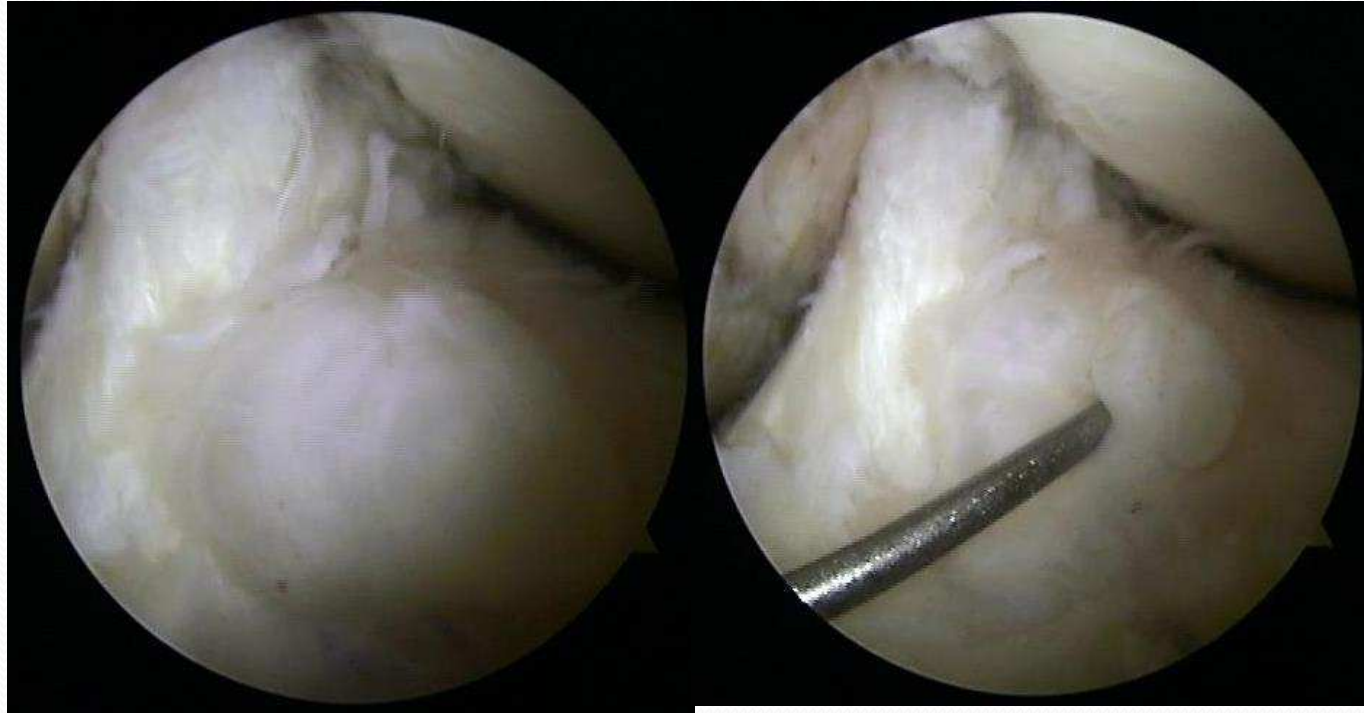
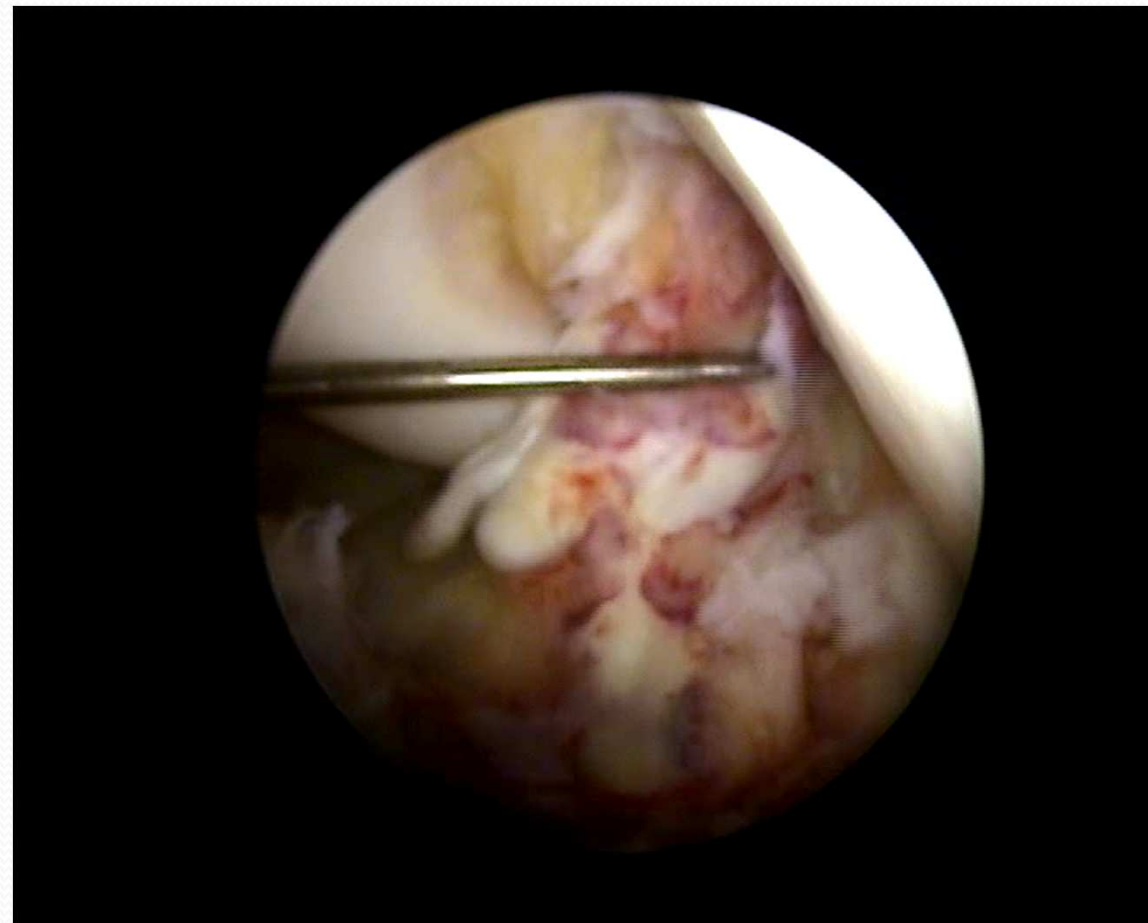




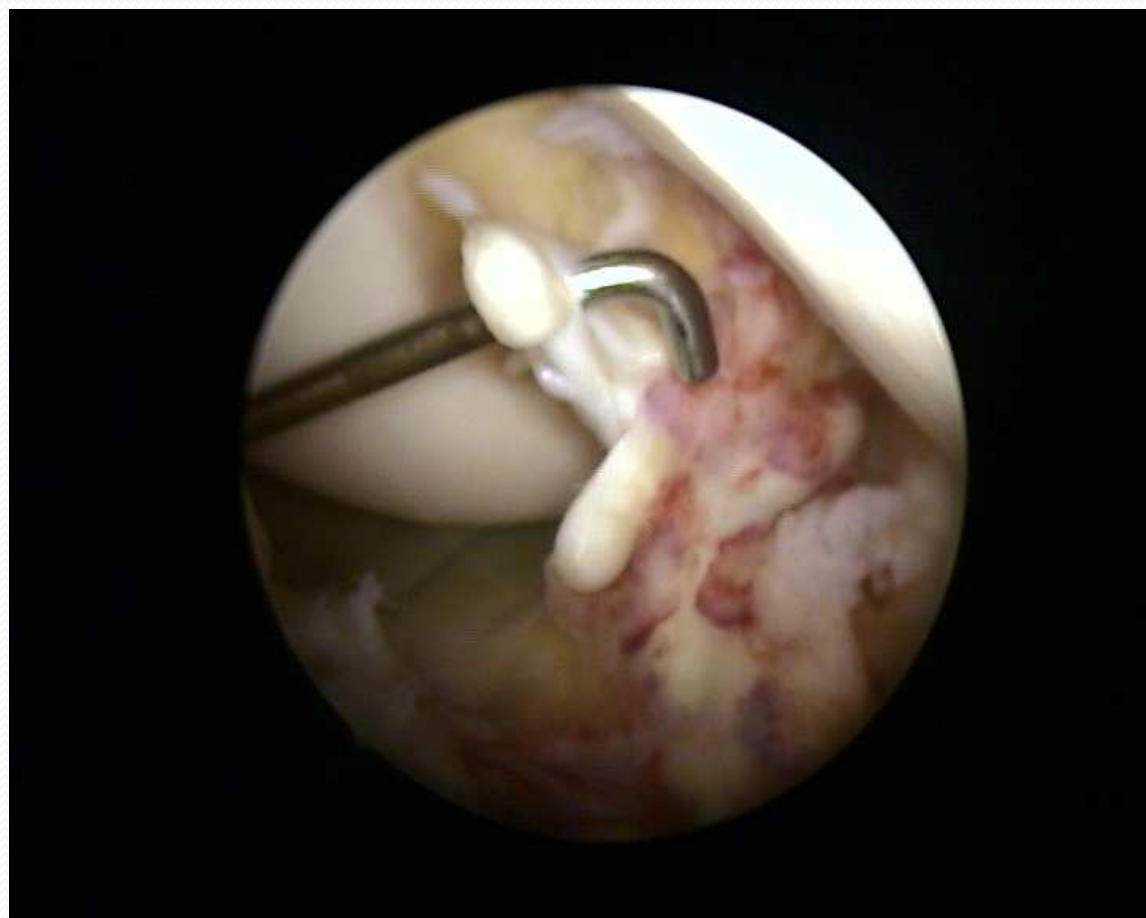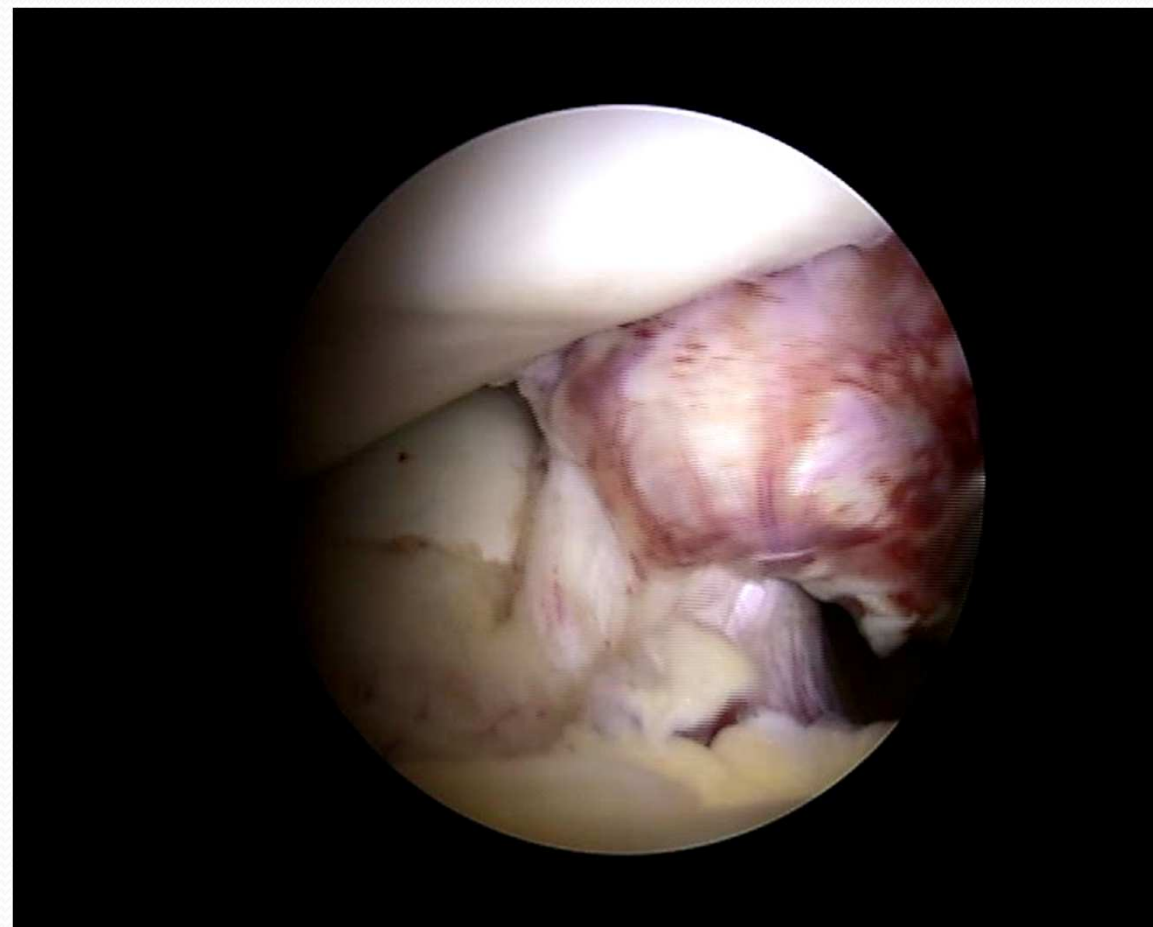
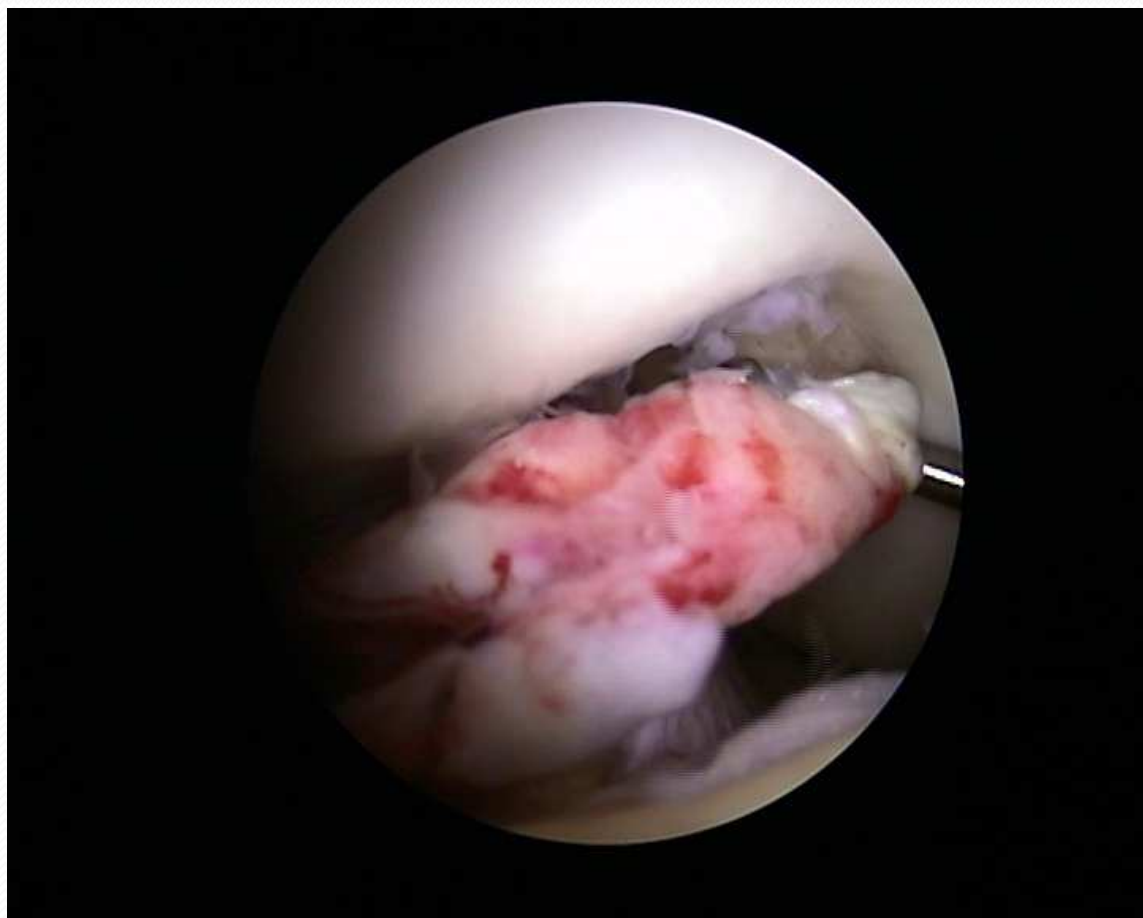
Cysta LCA



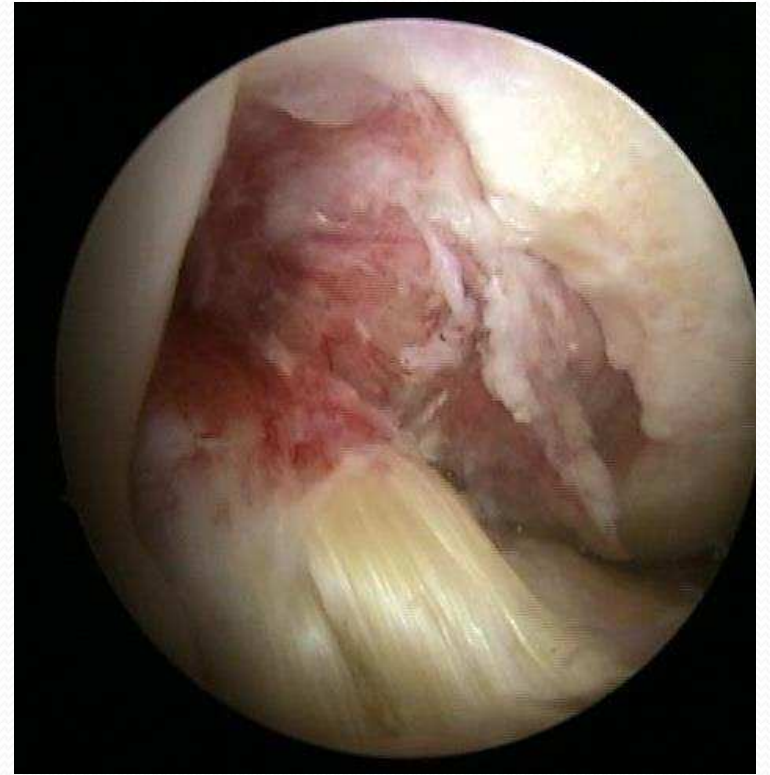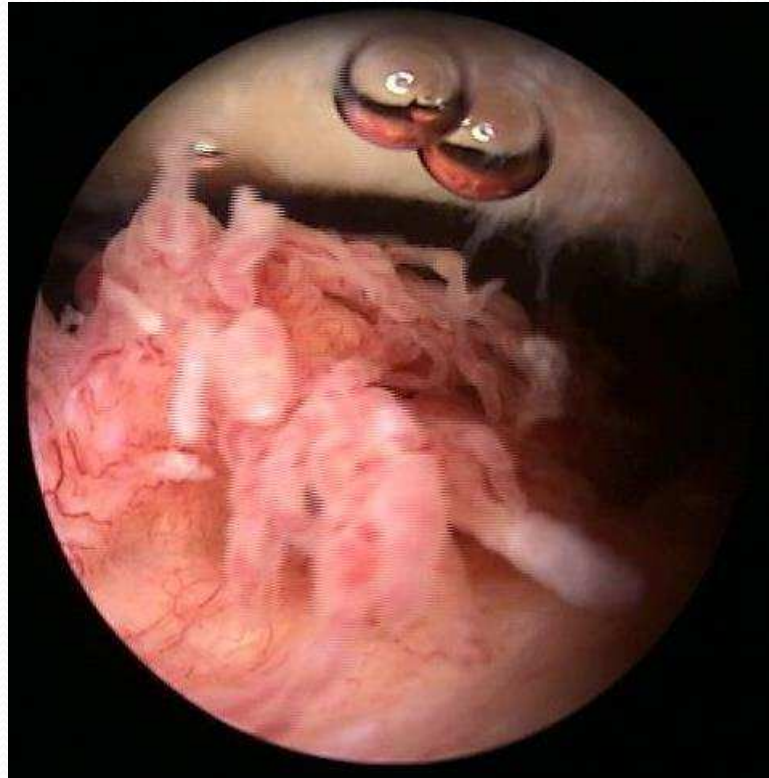
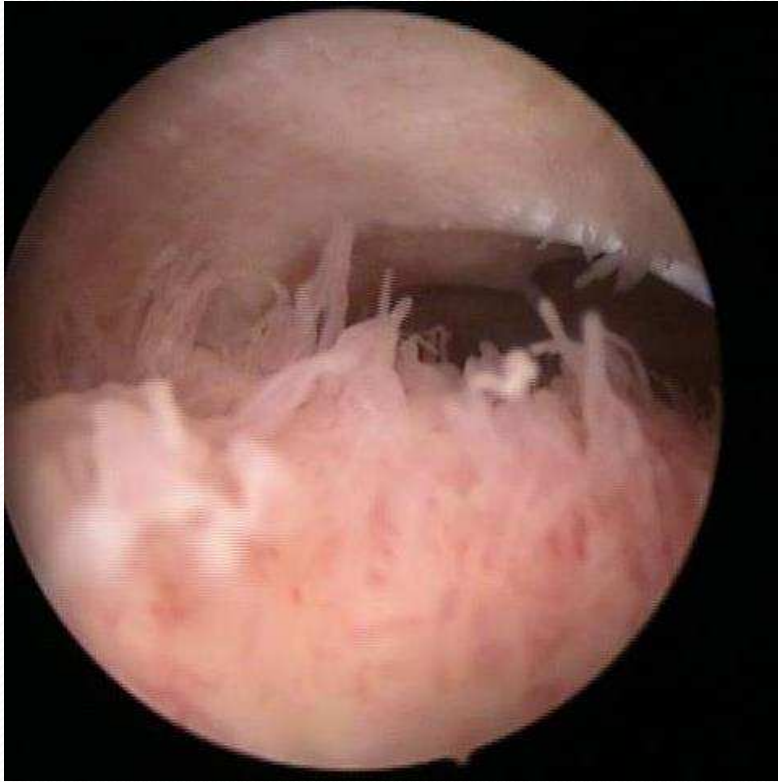LCA akútna lézia



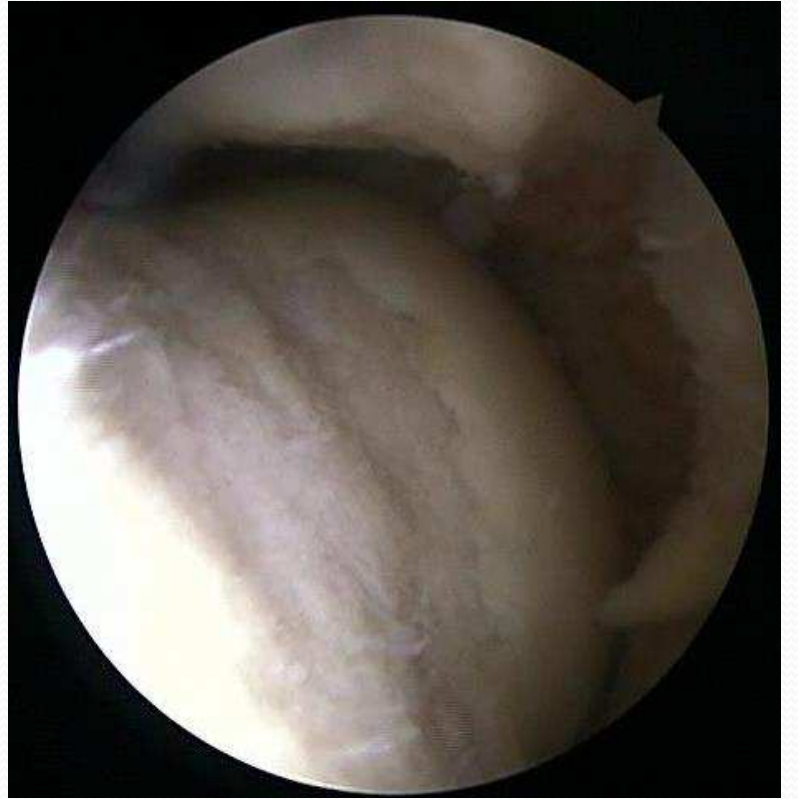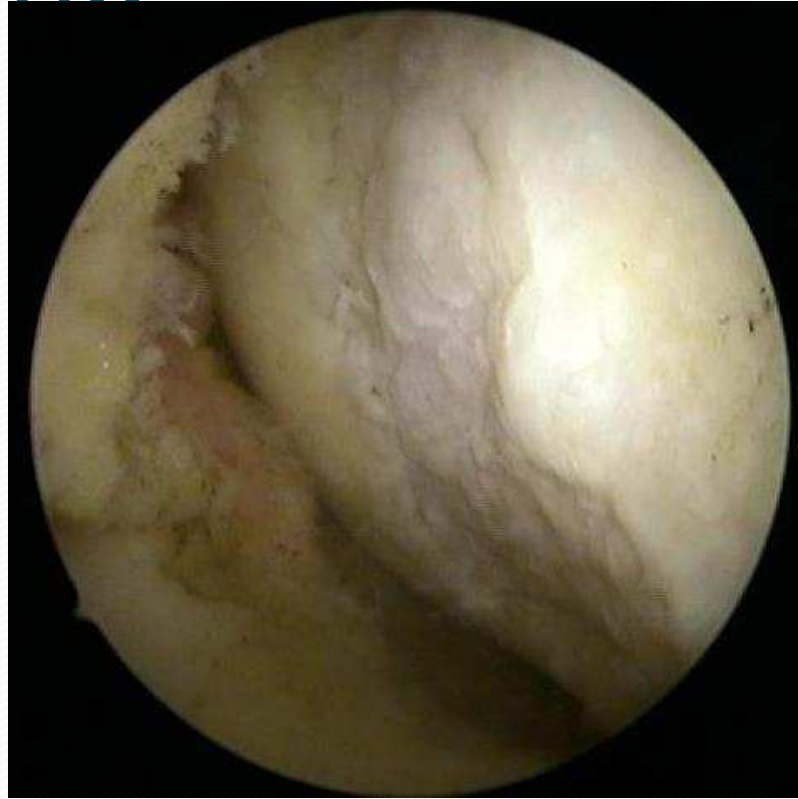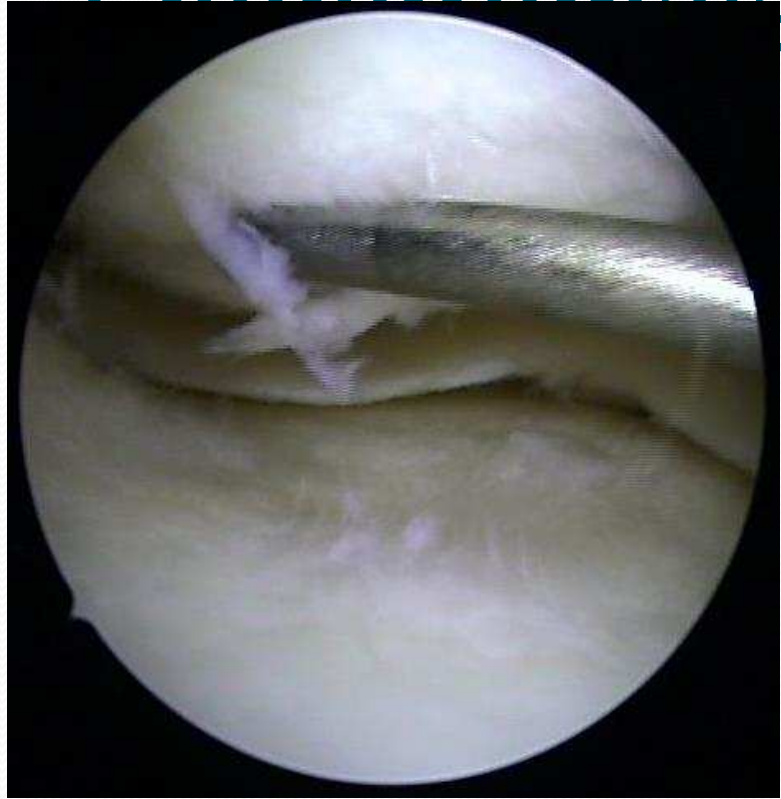LCA akútna lézia

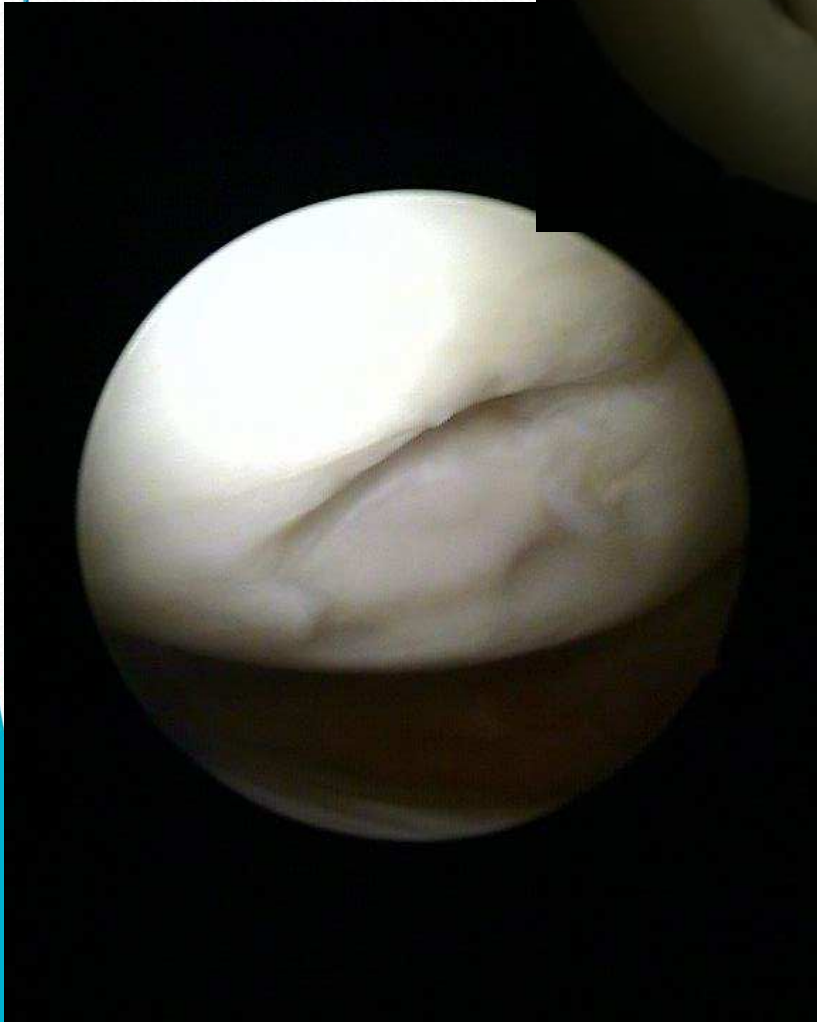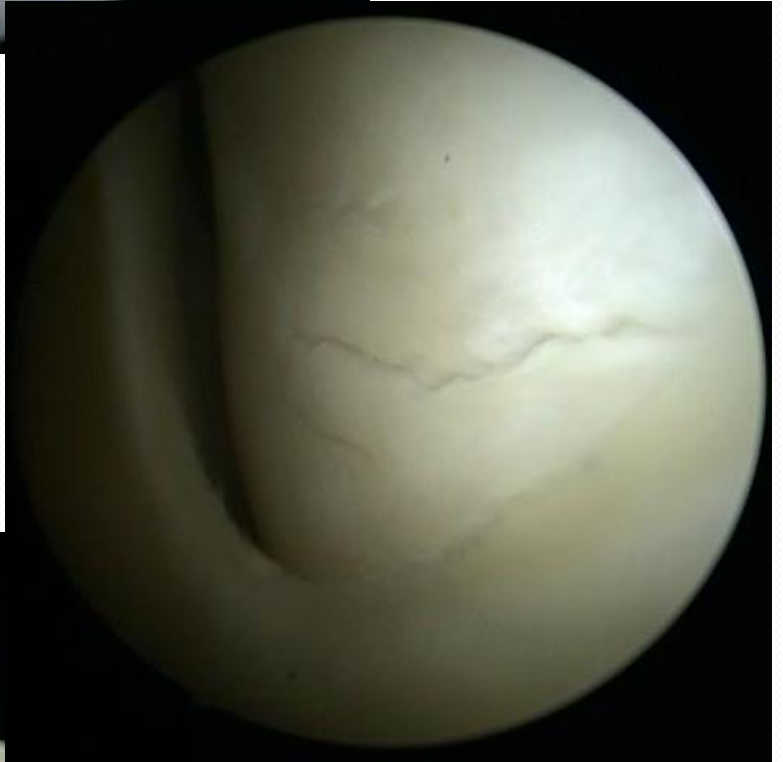
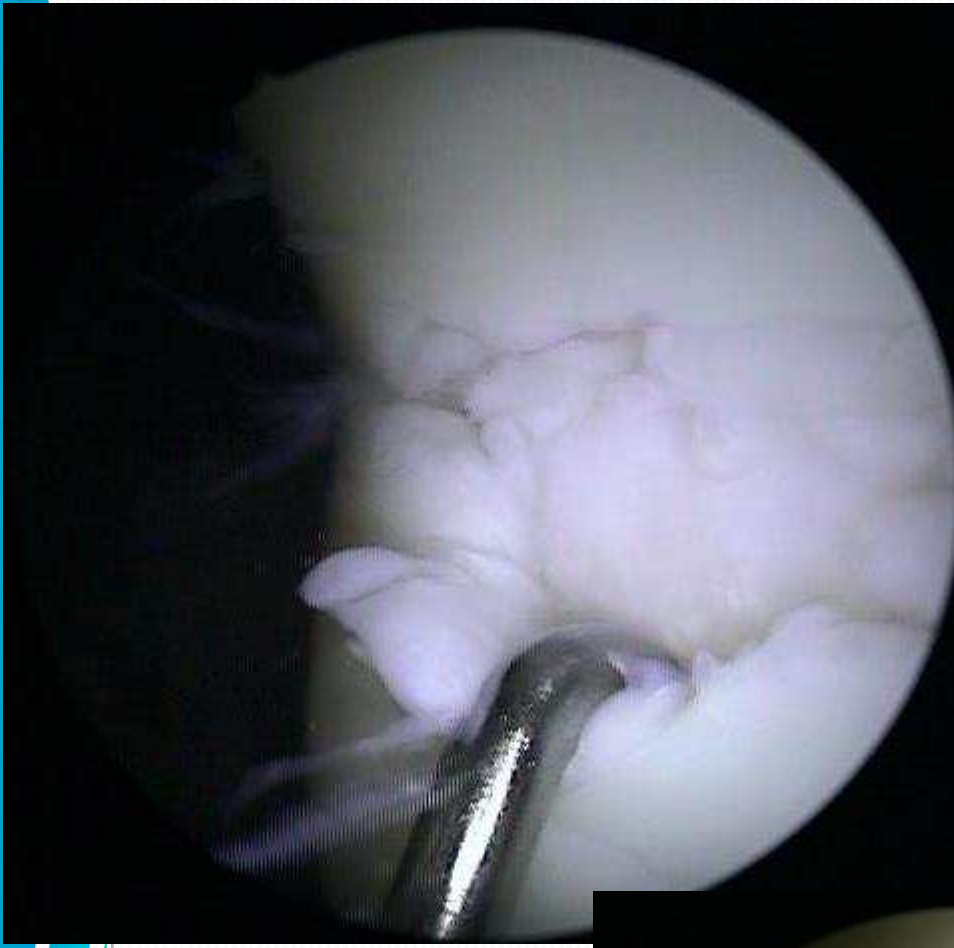


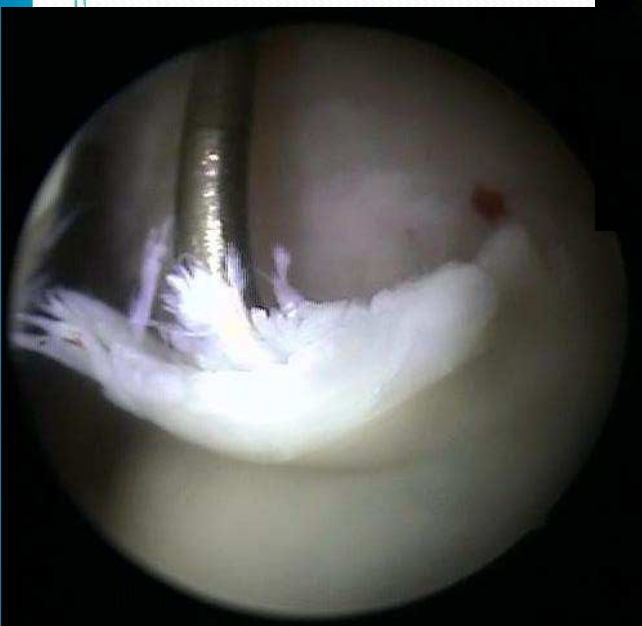

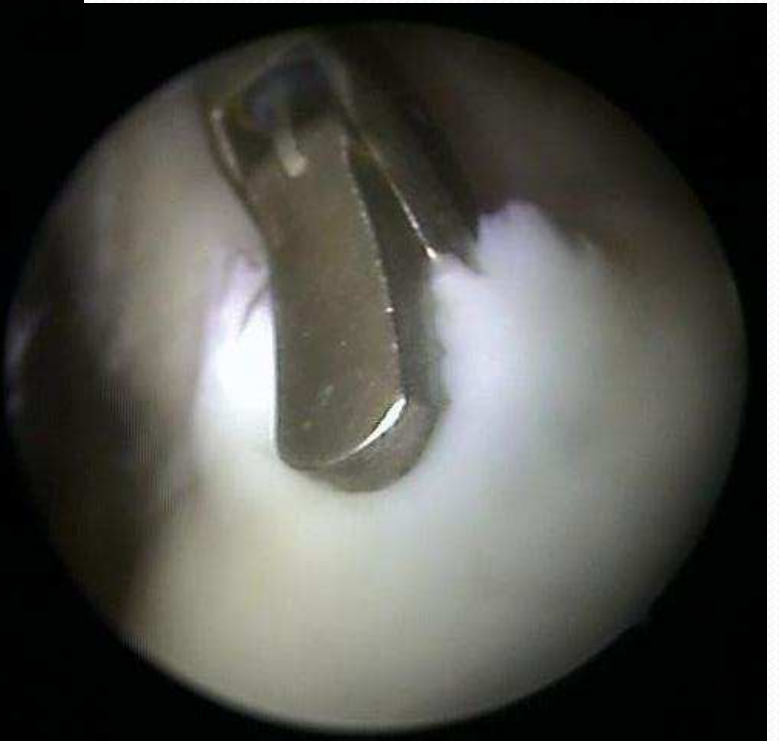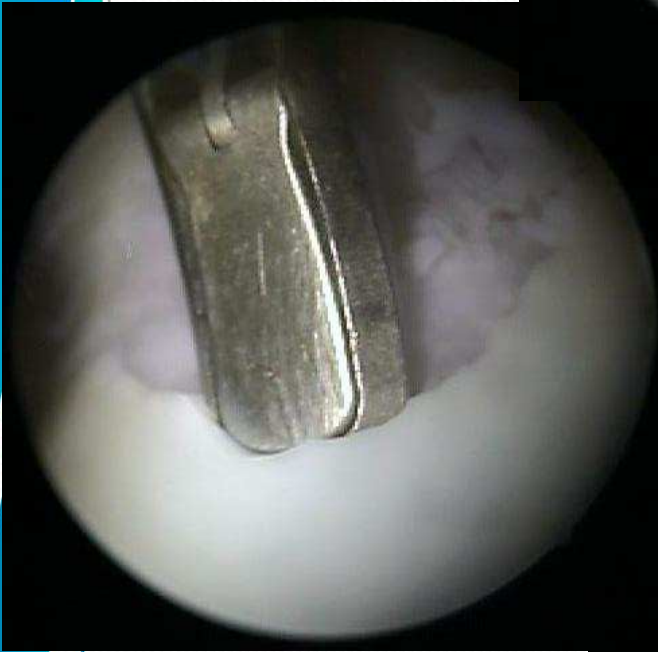
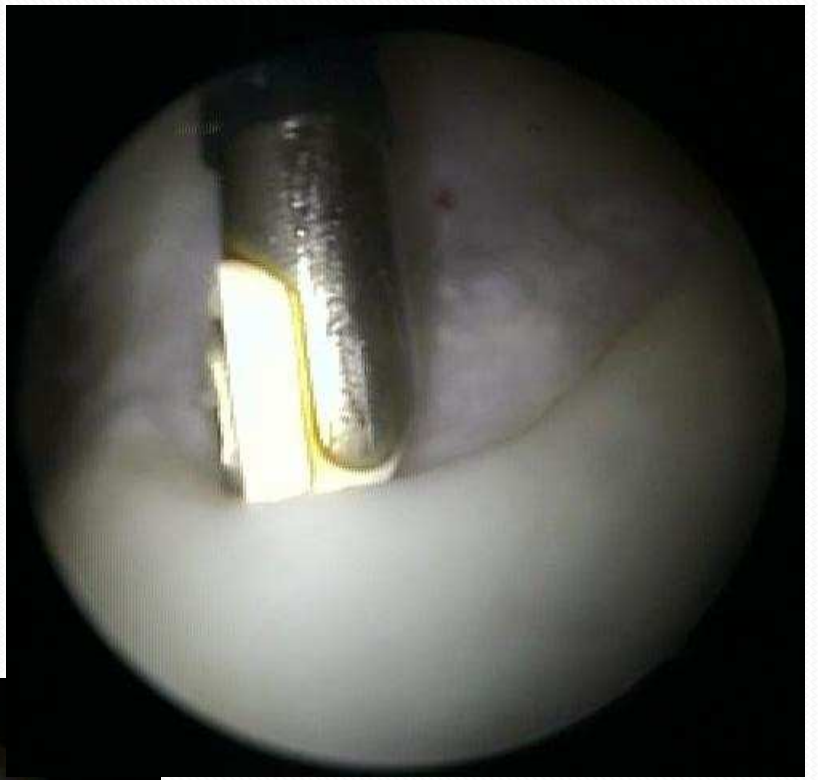
Synovitis



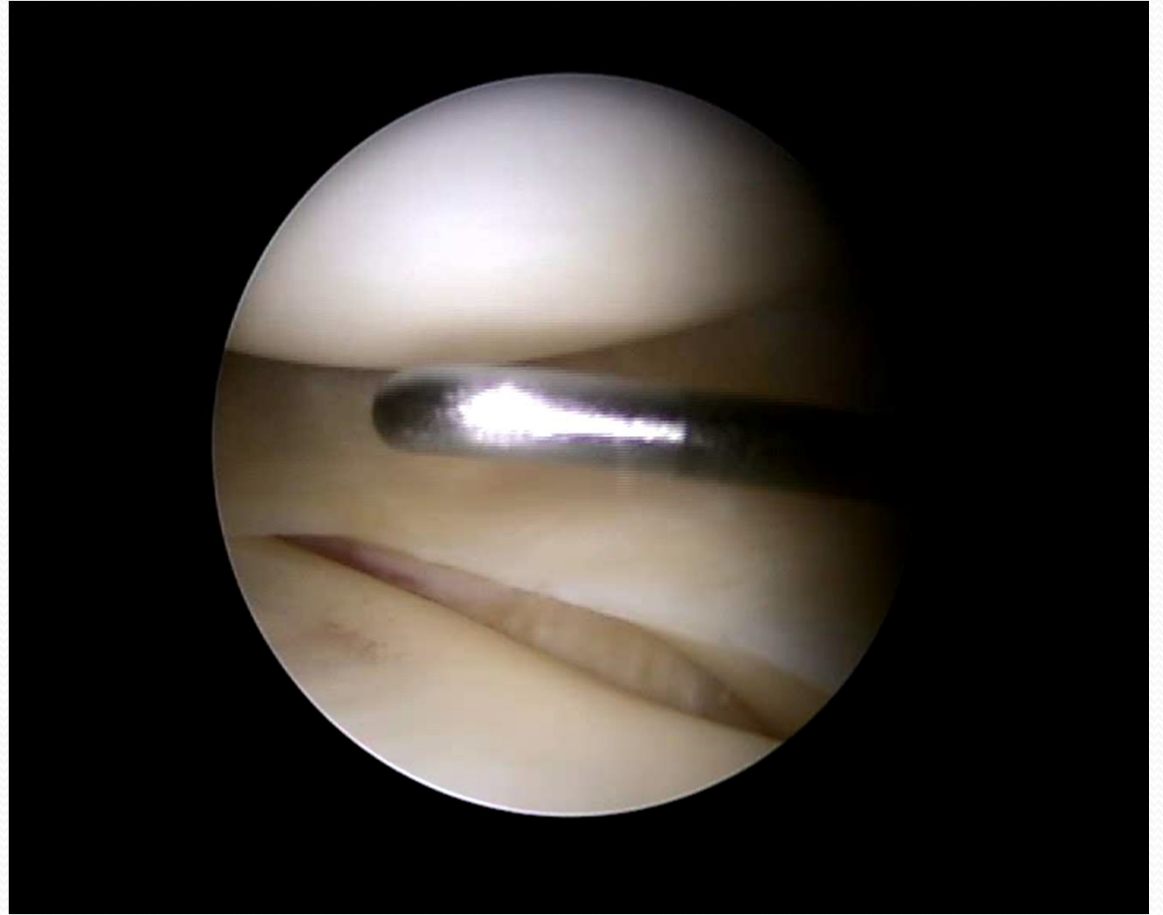
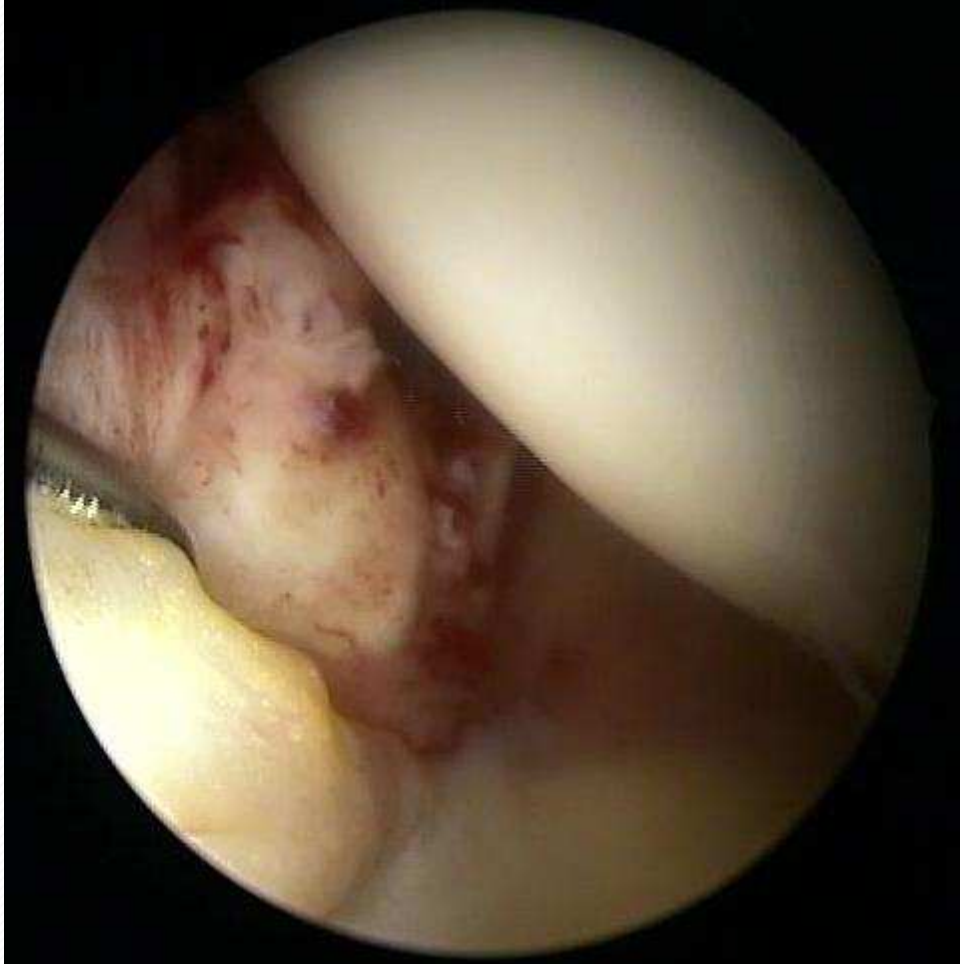
Chondromatosis



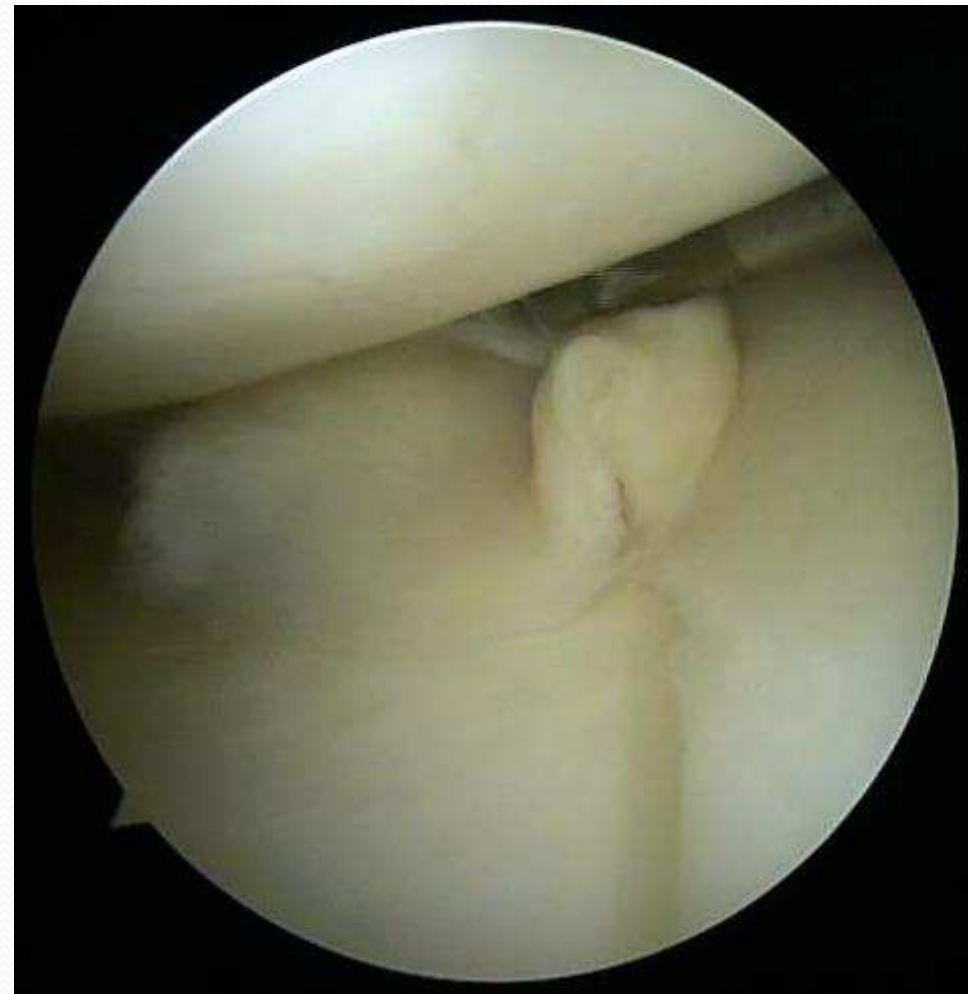
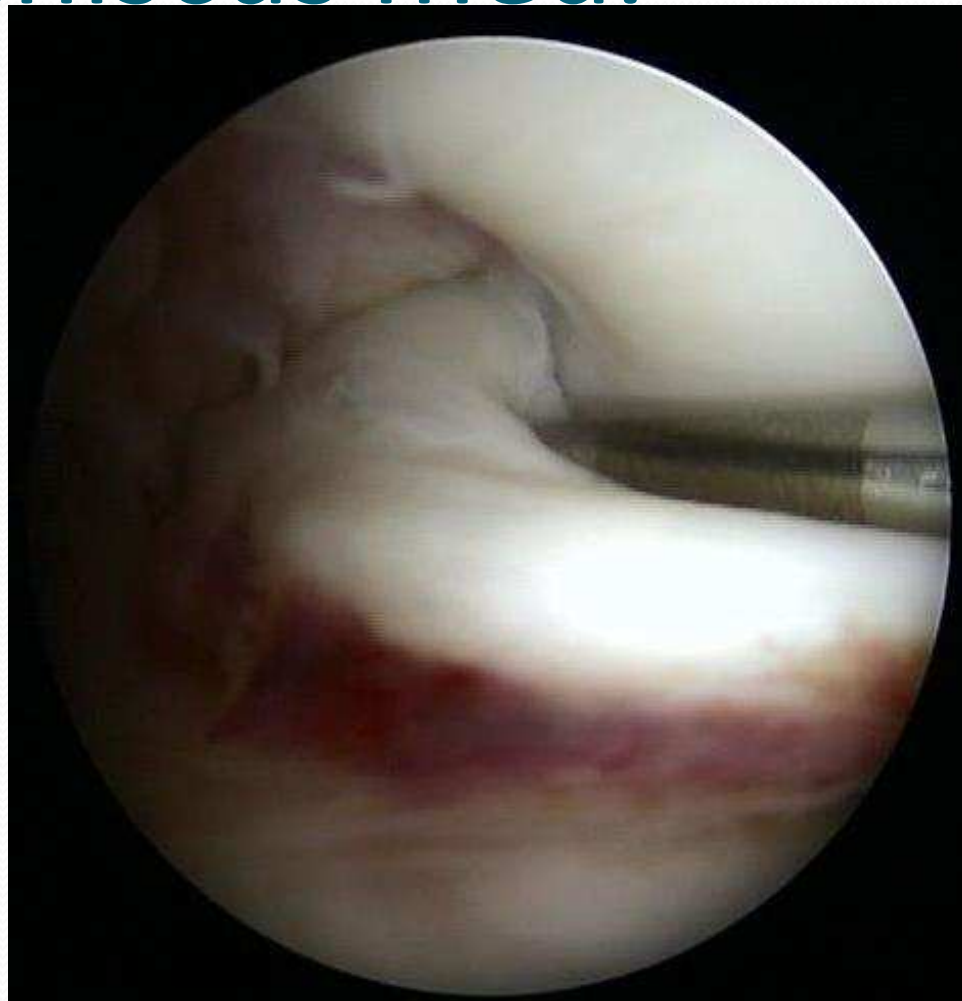


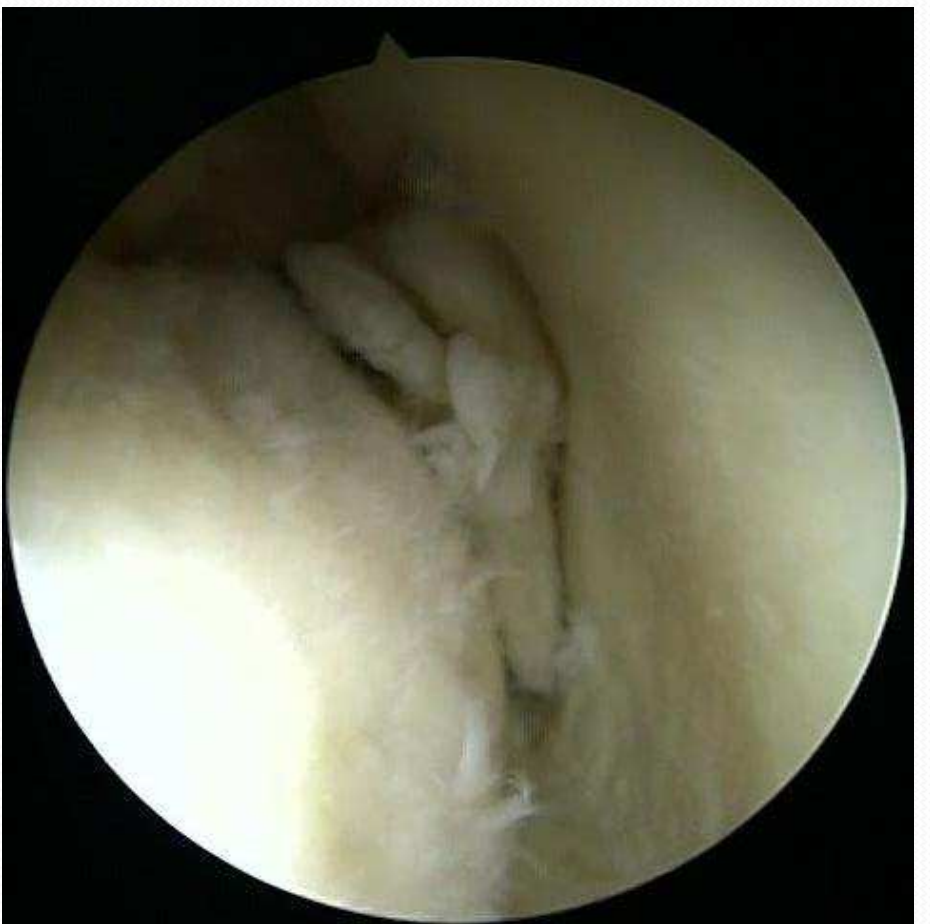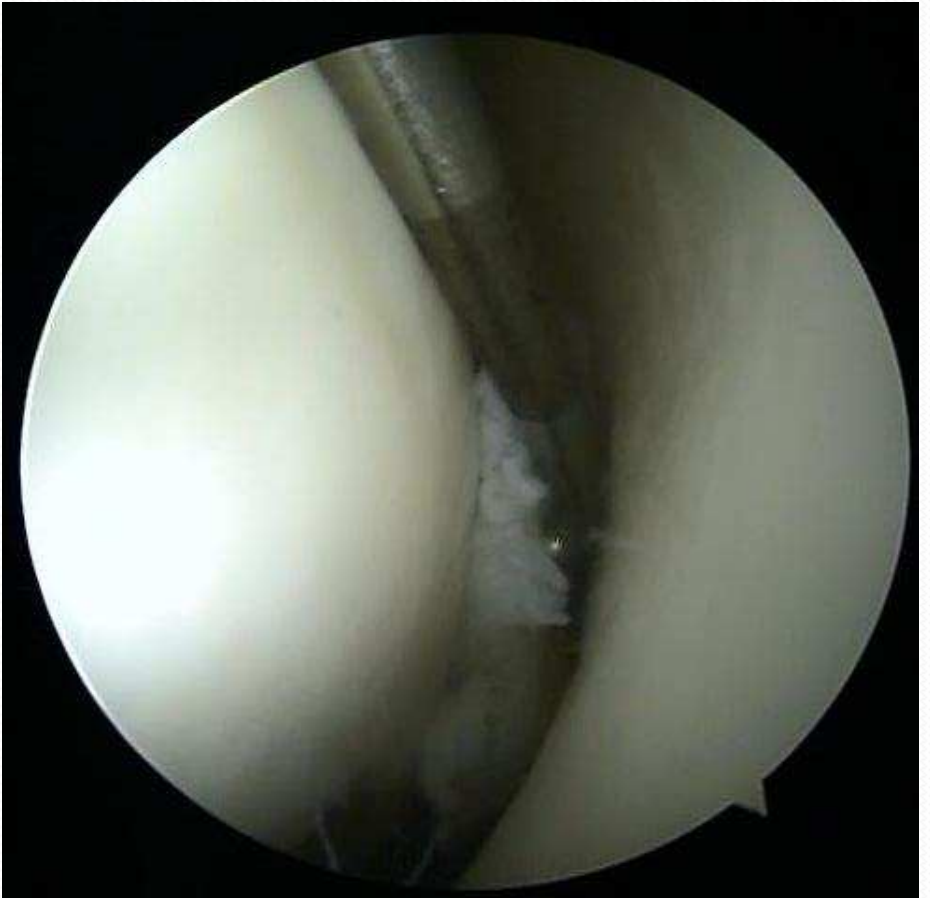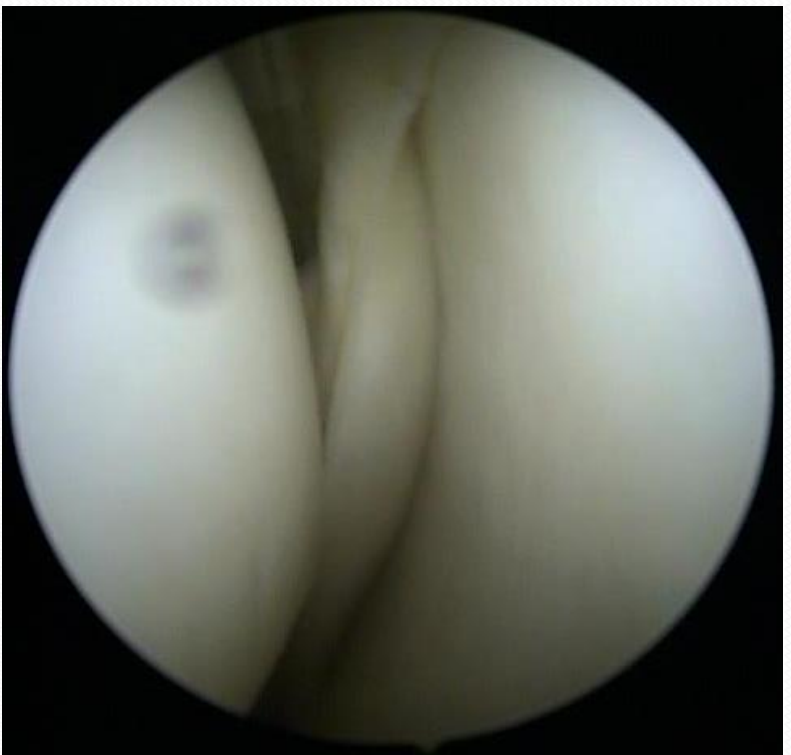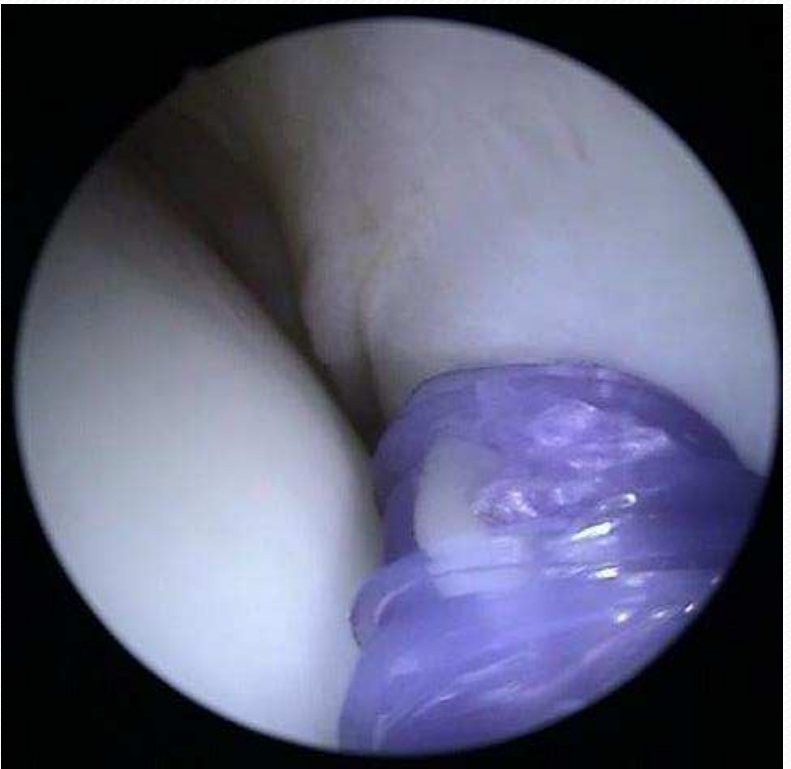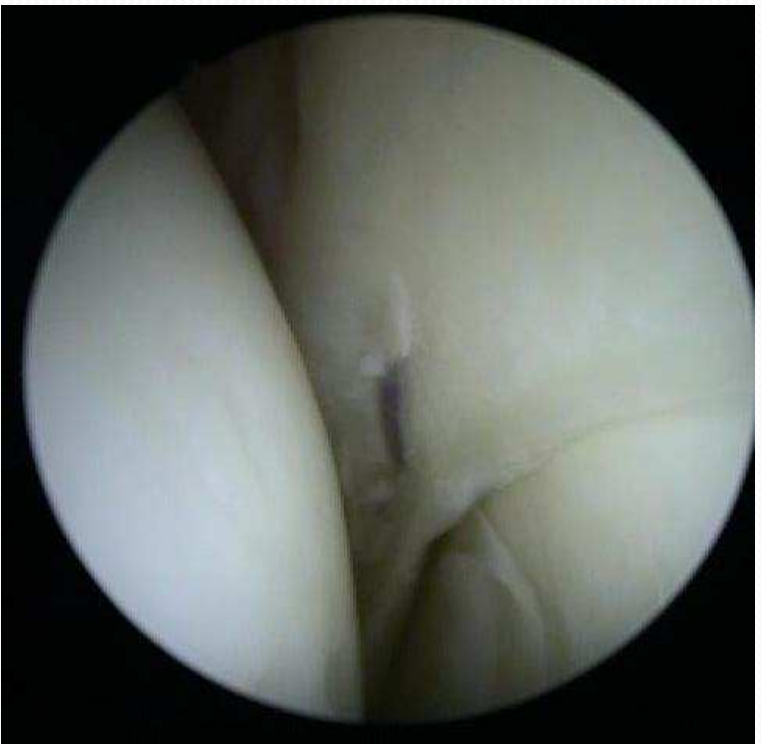LCM

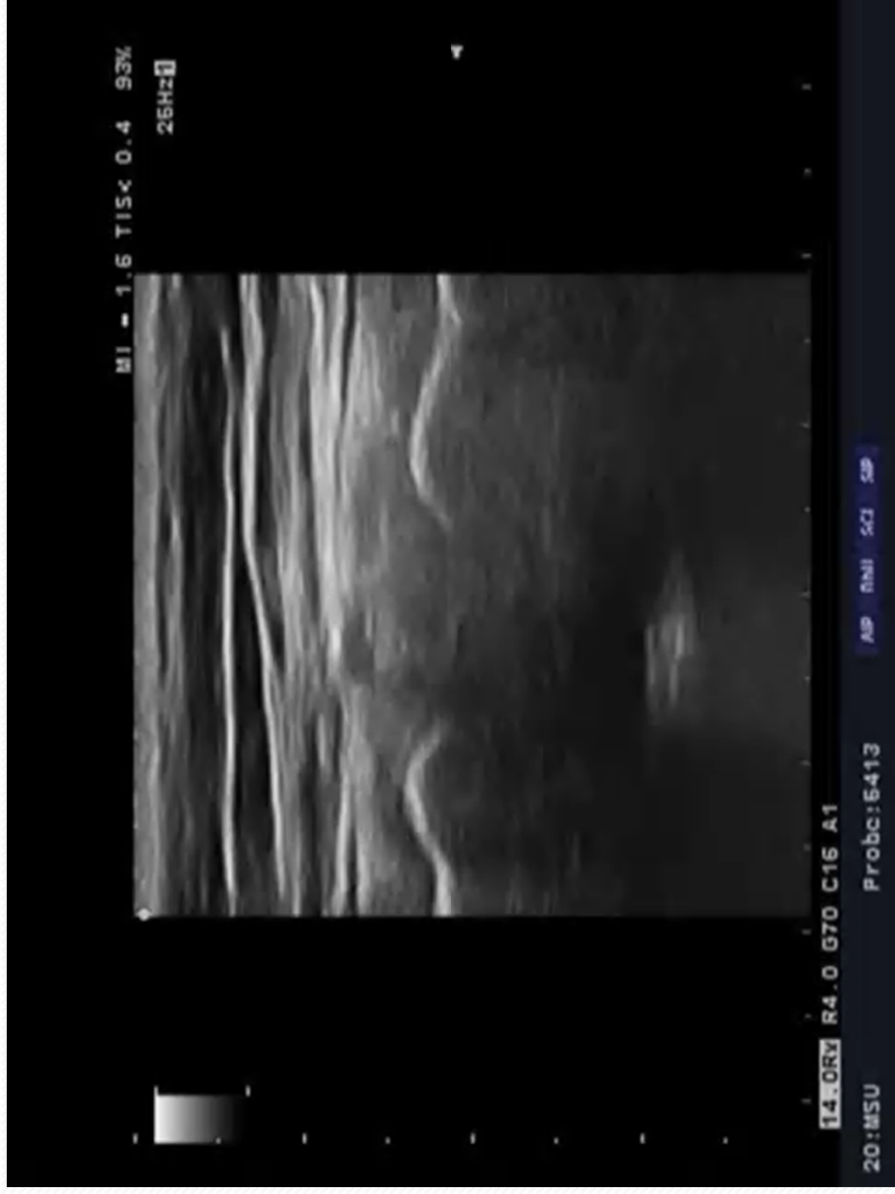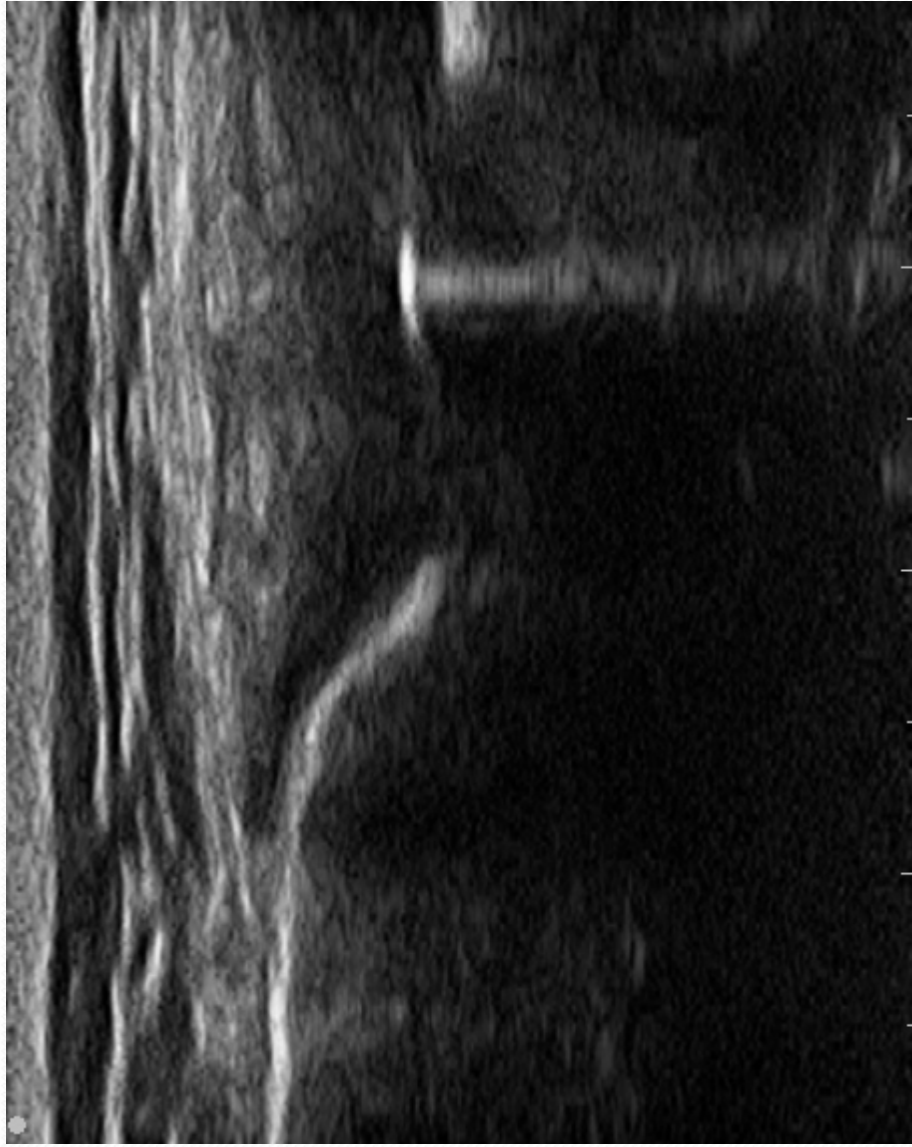


Meniscus med.

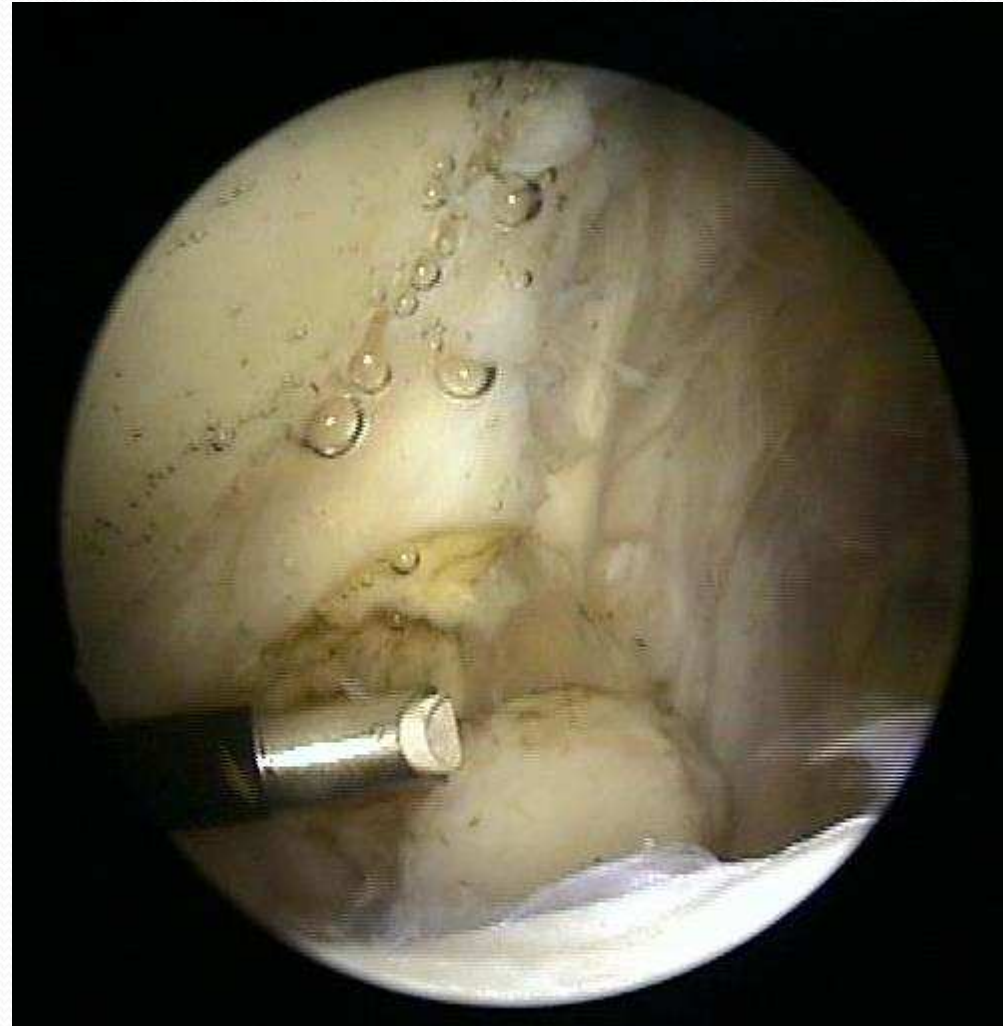
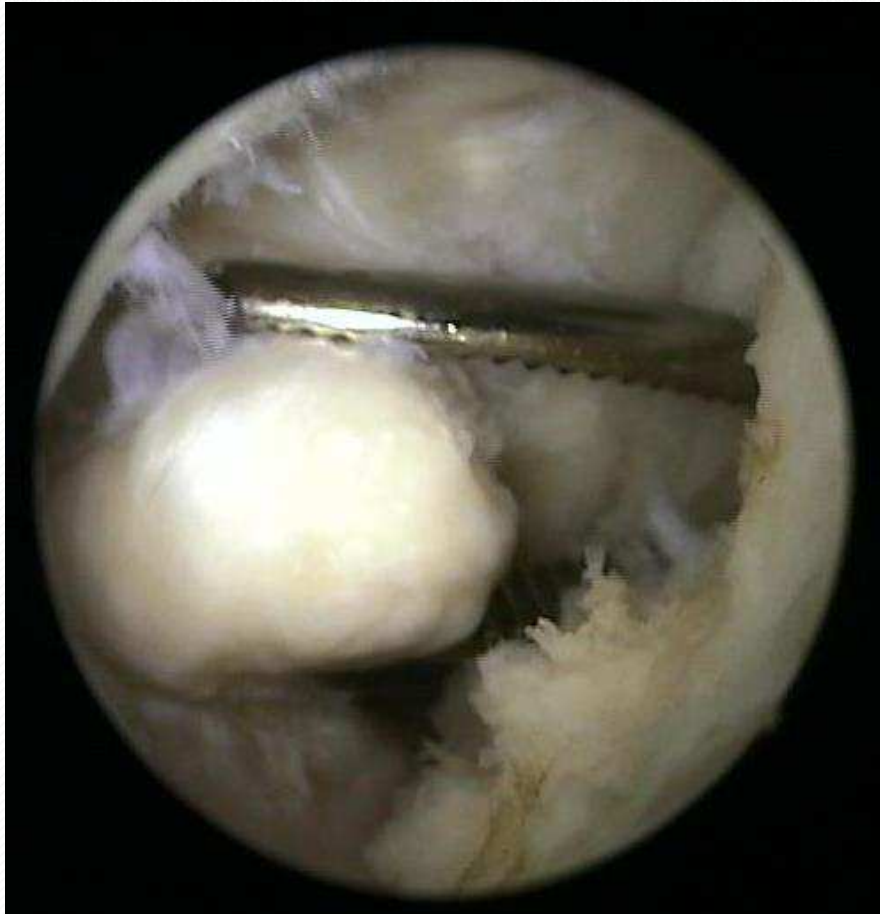




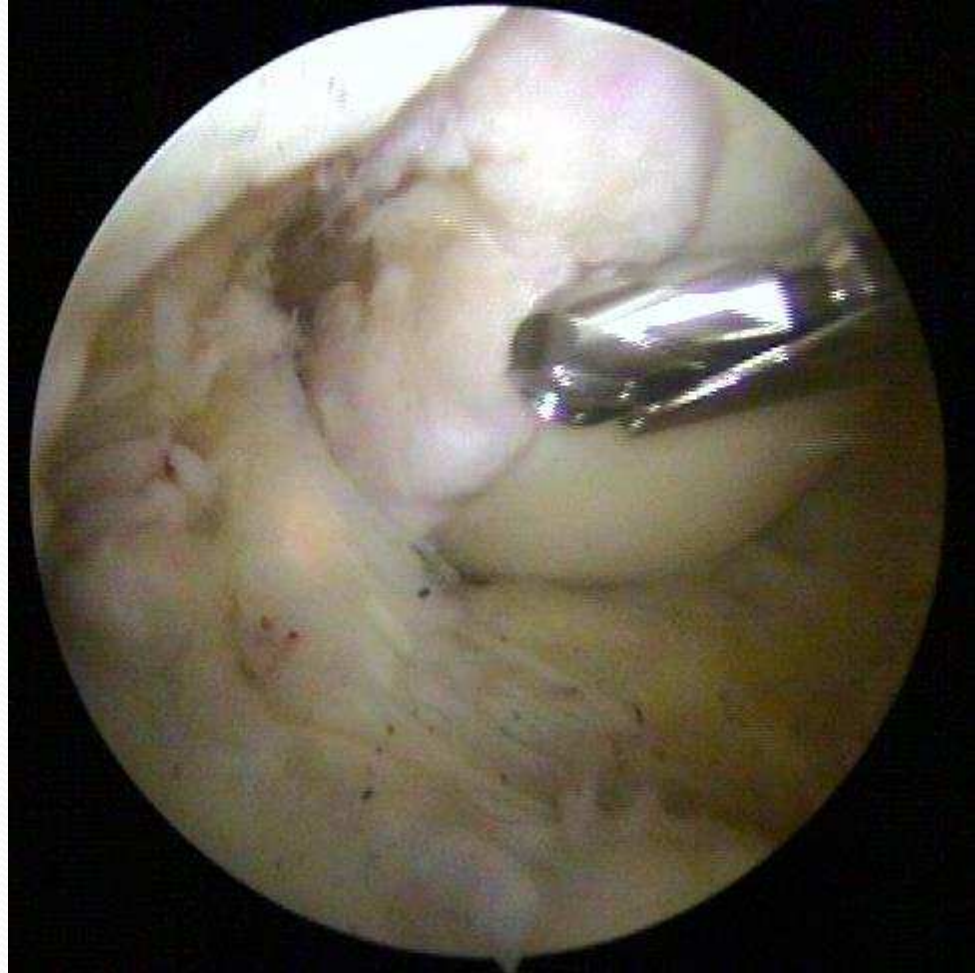
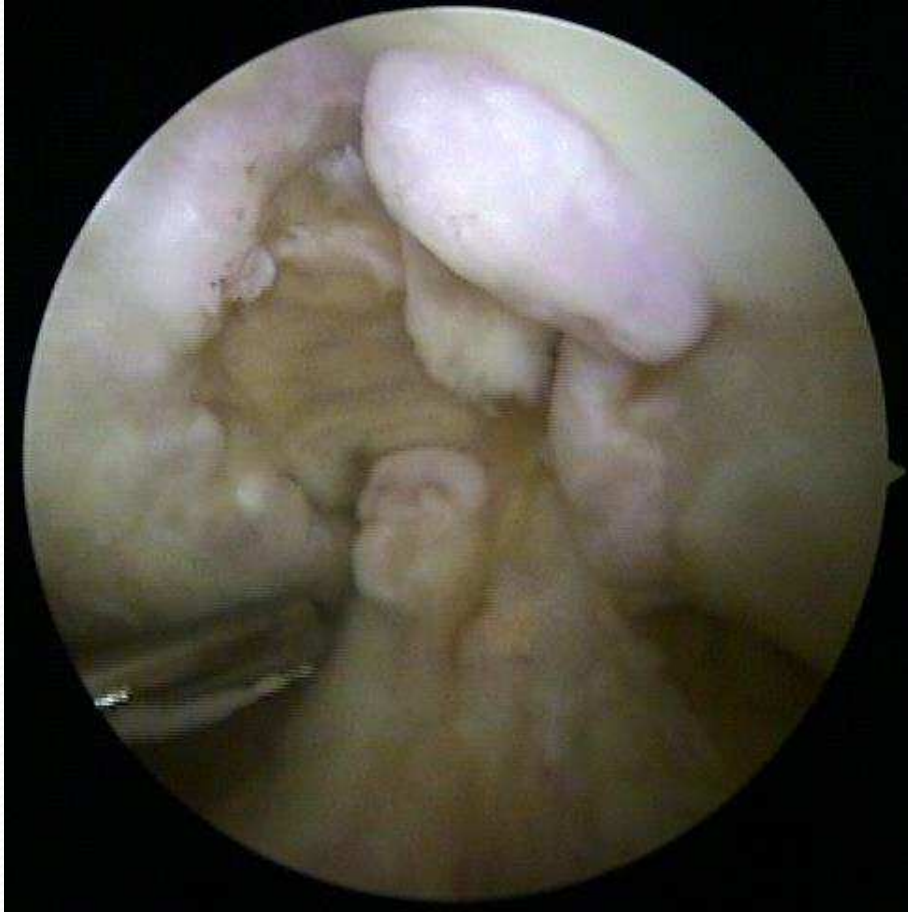
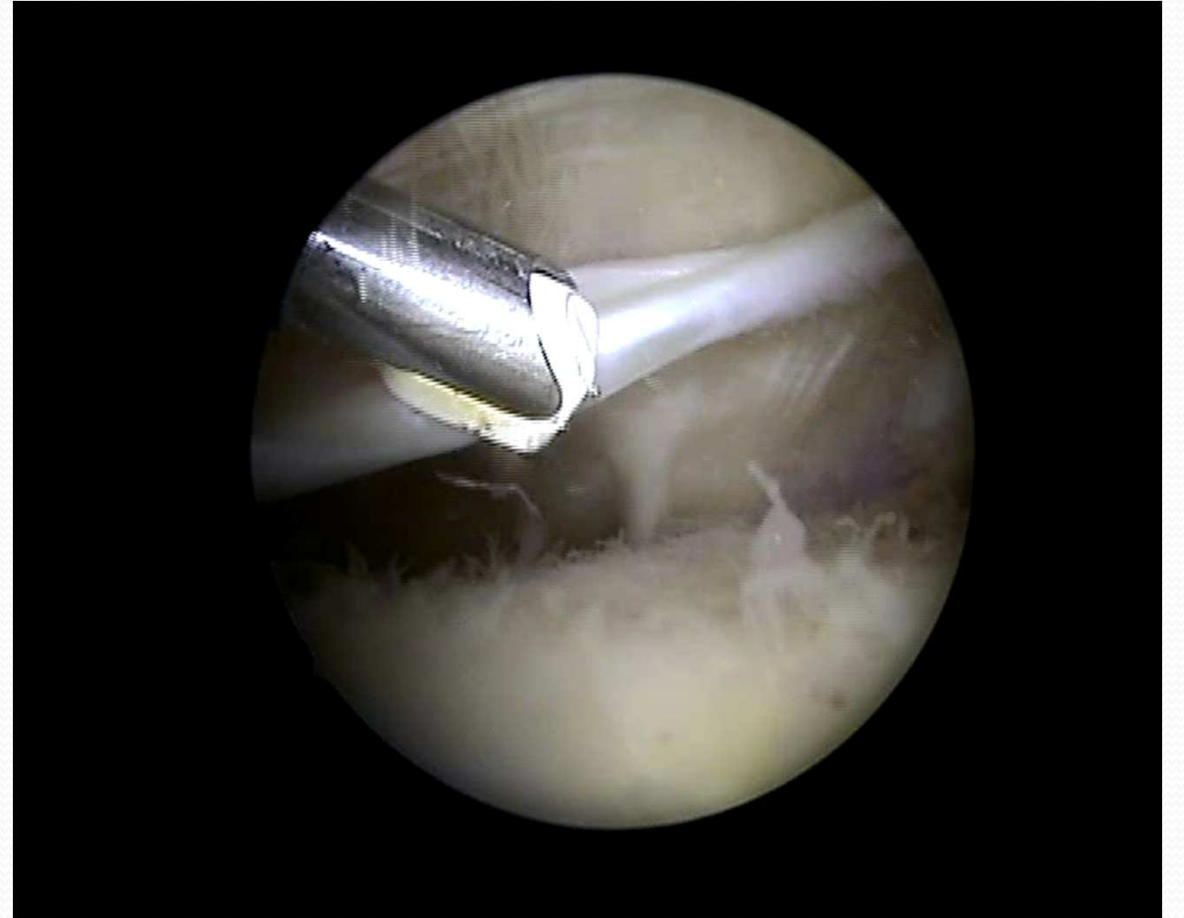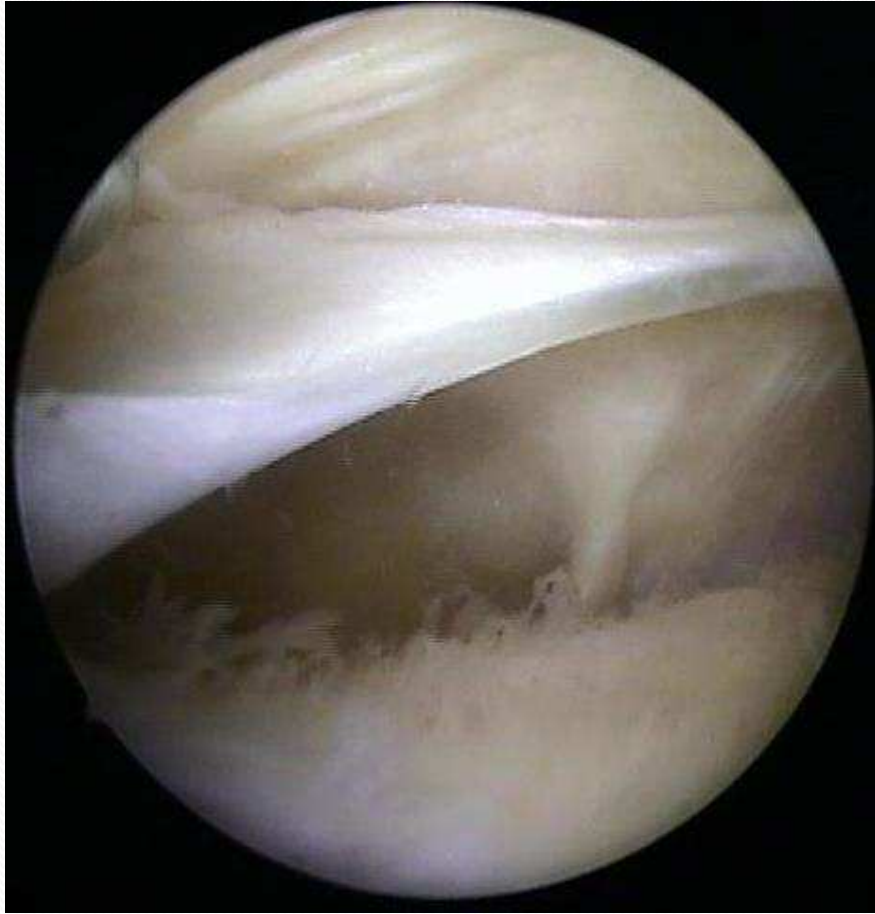Mus articulare



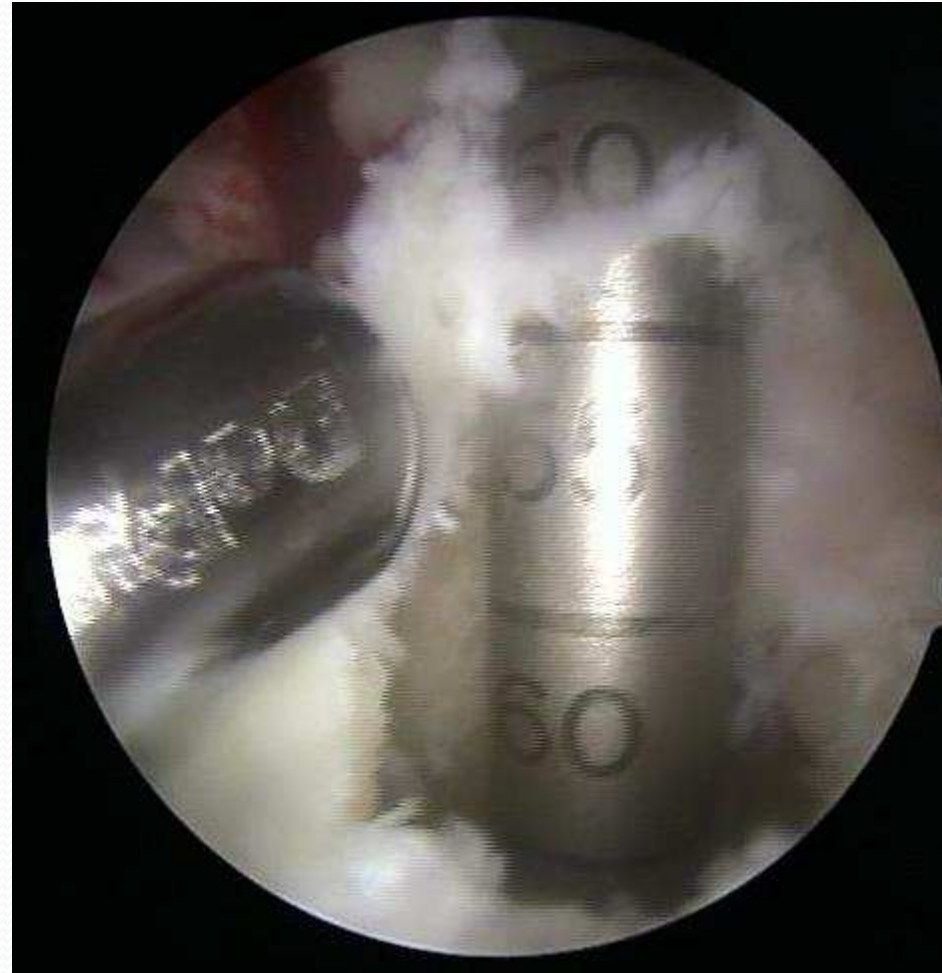
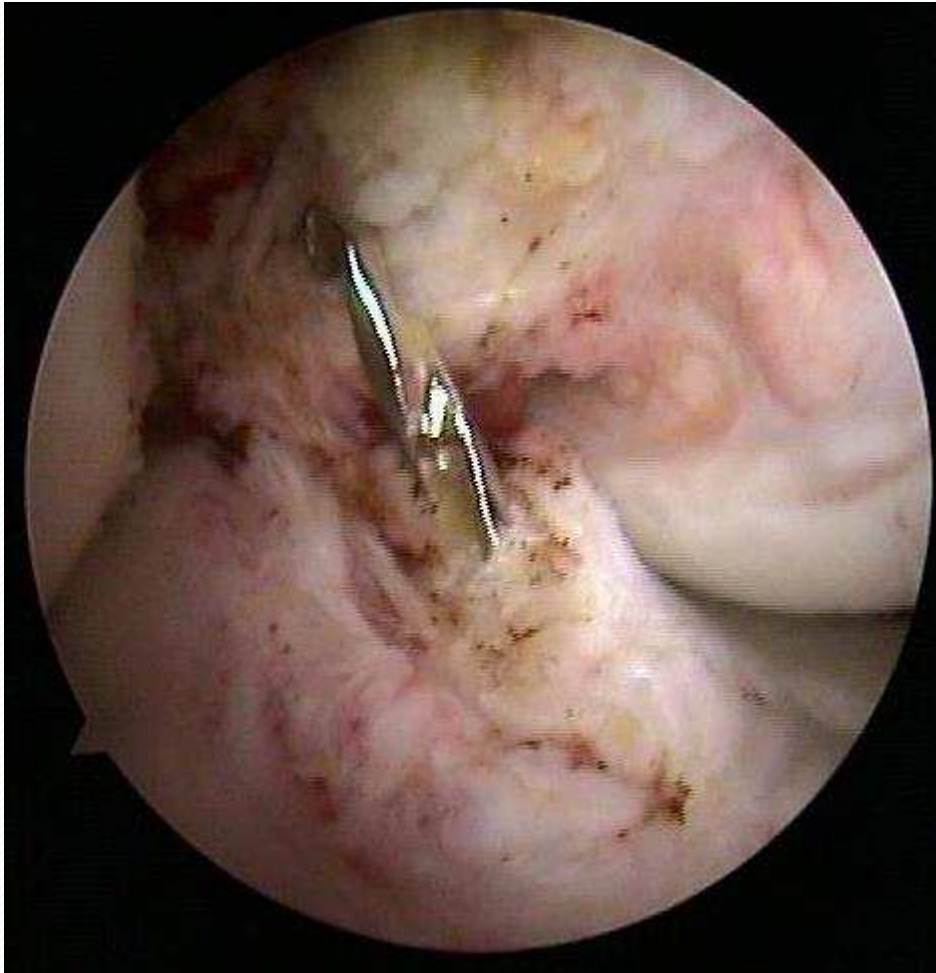
Osteofyty

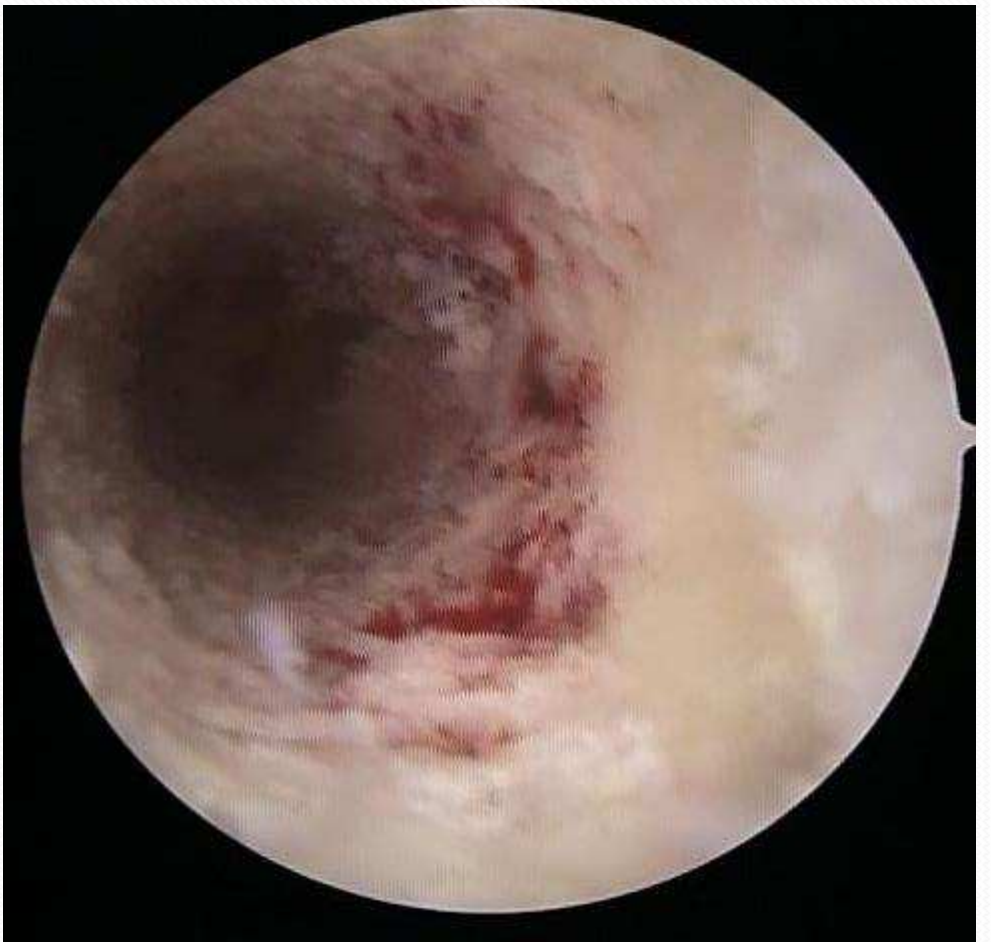
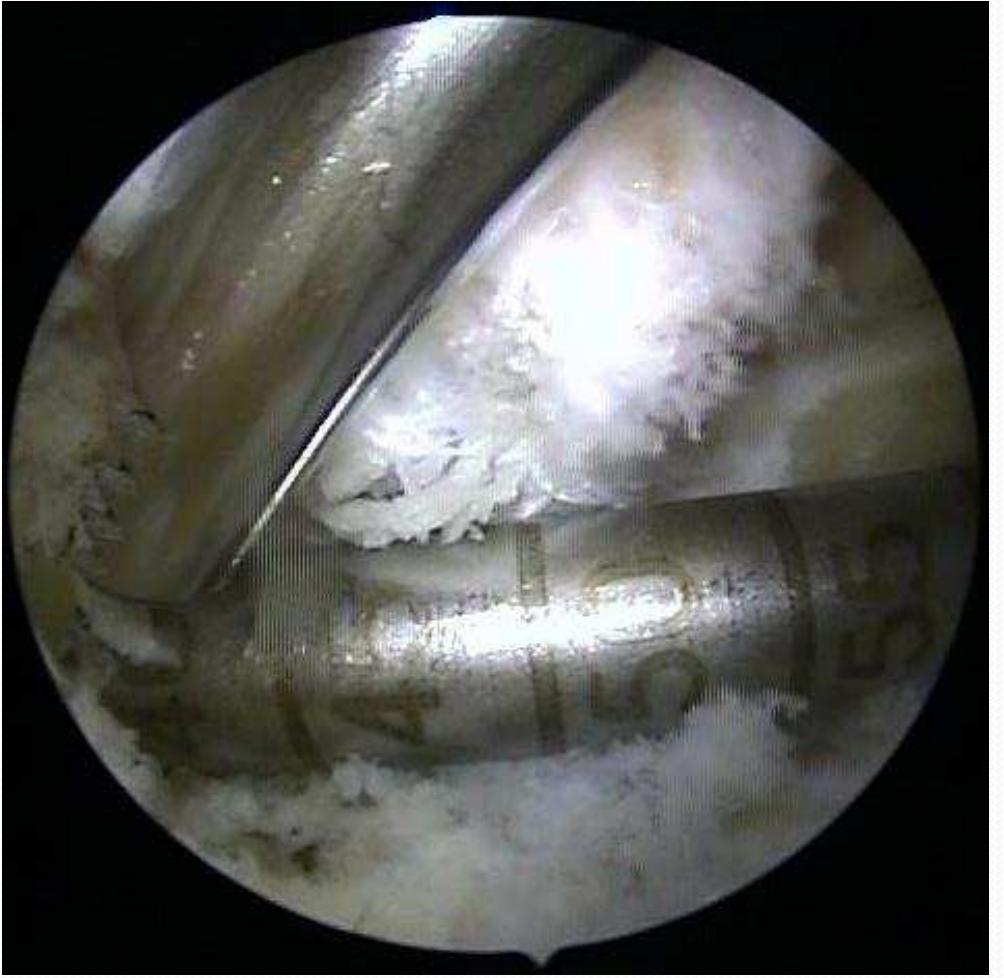
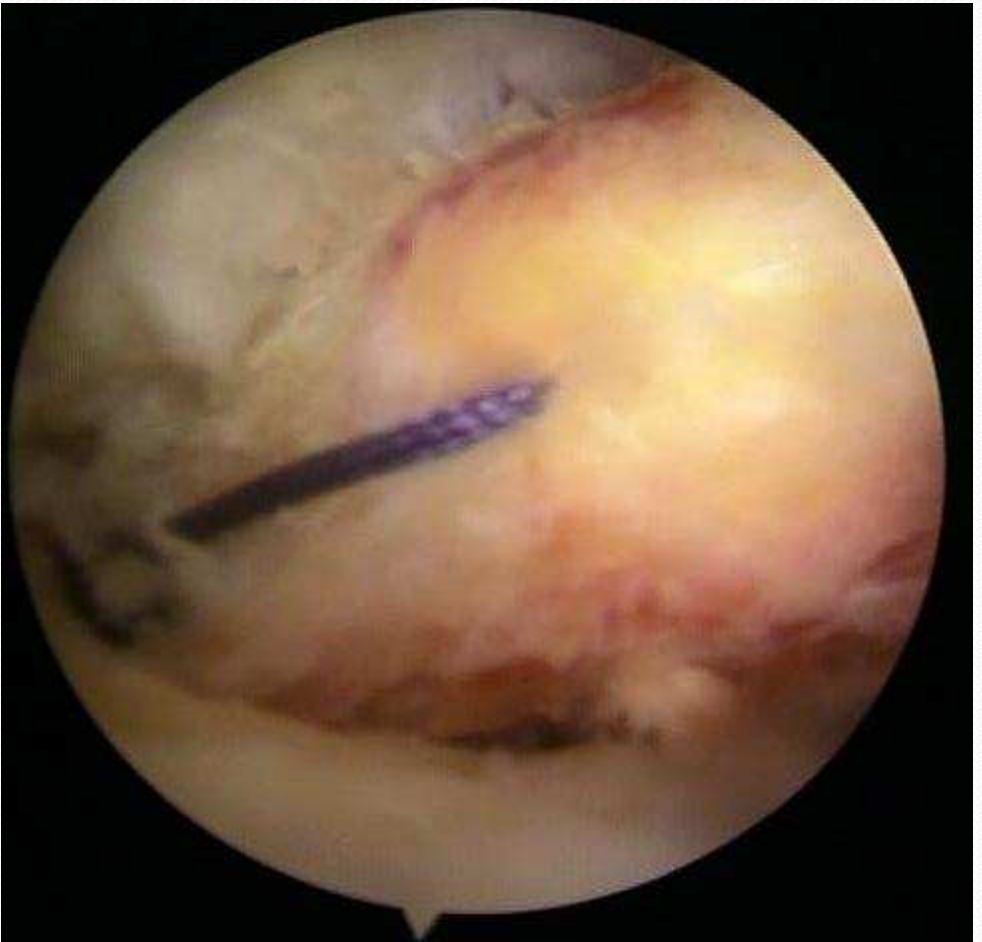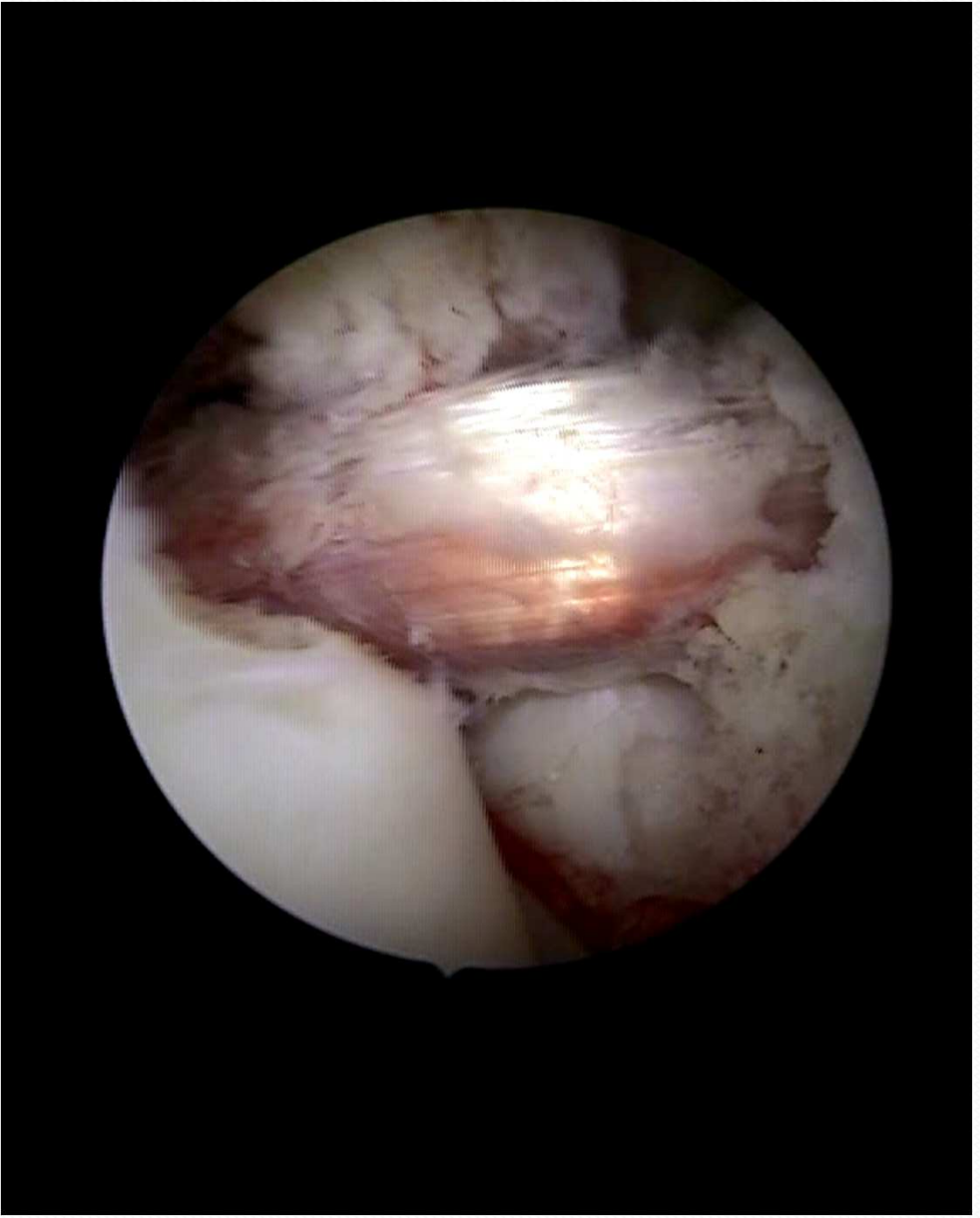Plica



LCA plastika







Hodnotenie bolesti a zmien, monitoring v kolennom kĺbe do 1r po artroskopickom debridmente pri artróze kolena

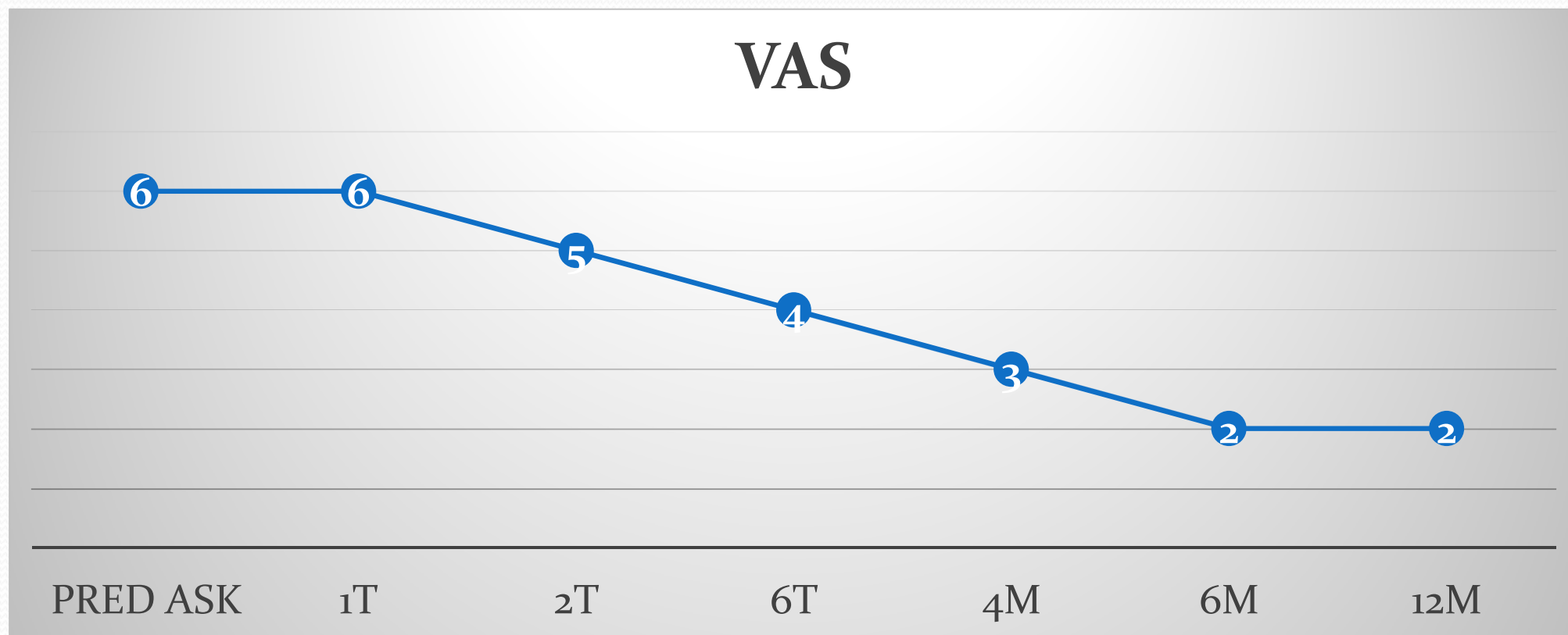
- Subjektívne hodnotenie pacientom - VAS
- RTG
 - stupeň artrózy
- USG
 - hlavne synovitídu s výpotokom
- Vzťah synovitídy s VAS

Pacienti a metodika

- 30 pacientov: 18 žien (60%), 12 mužov (40%)
- Vek 40 až 60 rokov
- 2012-2014
- gonartróza
 - 3. stupňa (RTG Kellgren-Lawrence)
 - dekompenzácia gonartrózy
 - VAS: ≥ 4 viac ako 3 mesiace
 - USG – synovitída, výpotok, marginálne osteofyty, subluxácia meniskov, chondromalácia, Bakerová cysta, Doppler analýza synovie
- artroskopický debridement – shaving, koblácia chrupavky, synovie, ošetrovanie menisku, laváž, extrakcia voľných telies, parciálna synovektómia
- Po ask – pokračovanie konzervatívne: rehabilitácia, NSA, príp. injekčná liečba, redukcia BMI
- hodnotenie do 1r od ask

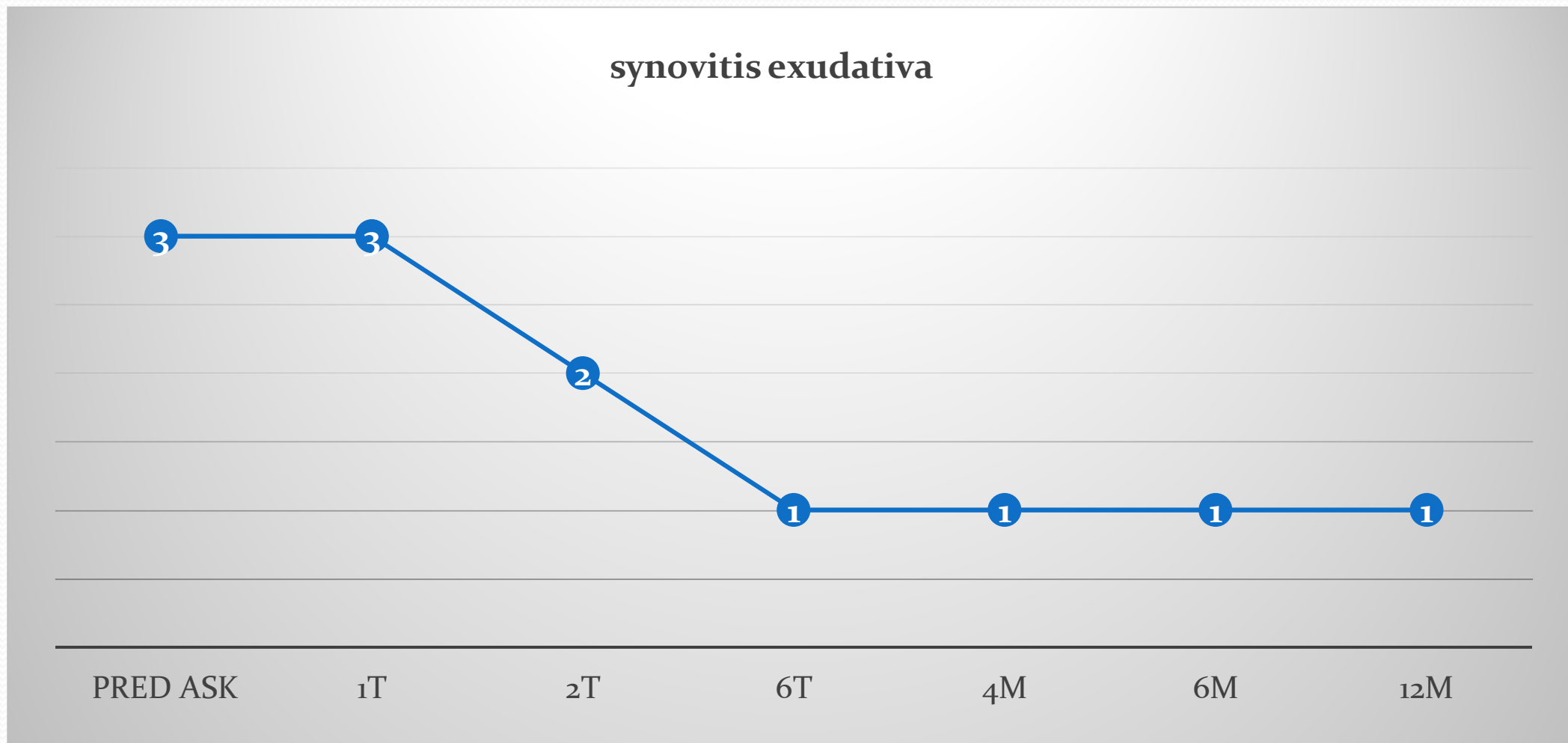
Výsledky

- Subjektívne hodnotenie pacientom – VAS
- pokles 6 na 2 do 1r



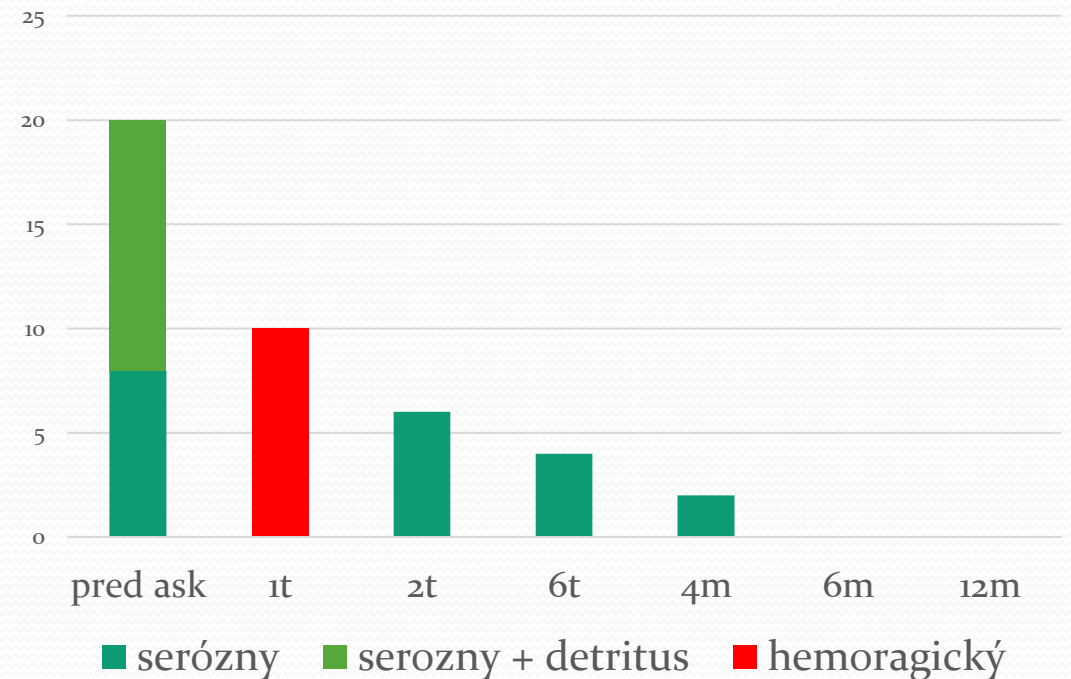
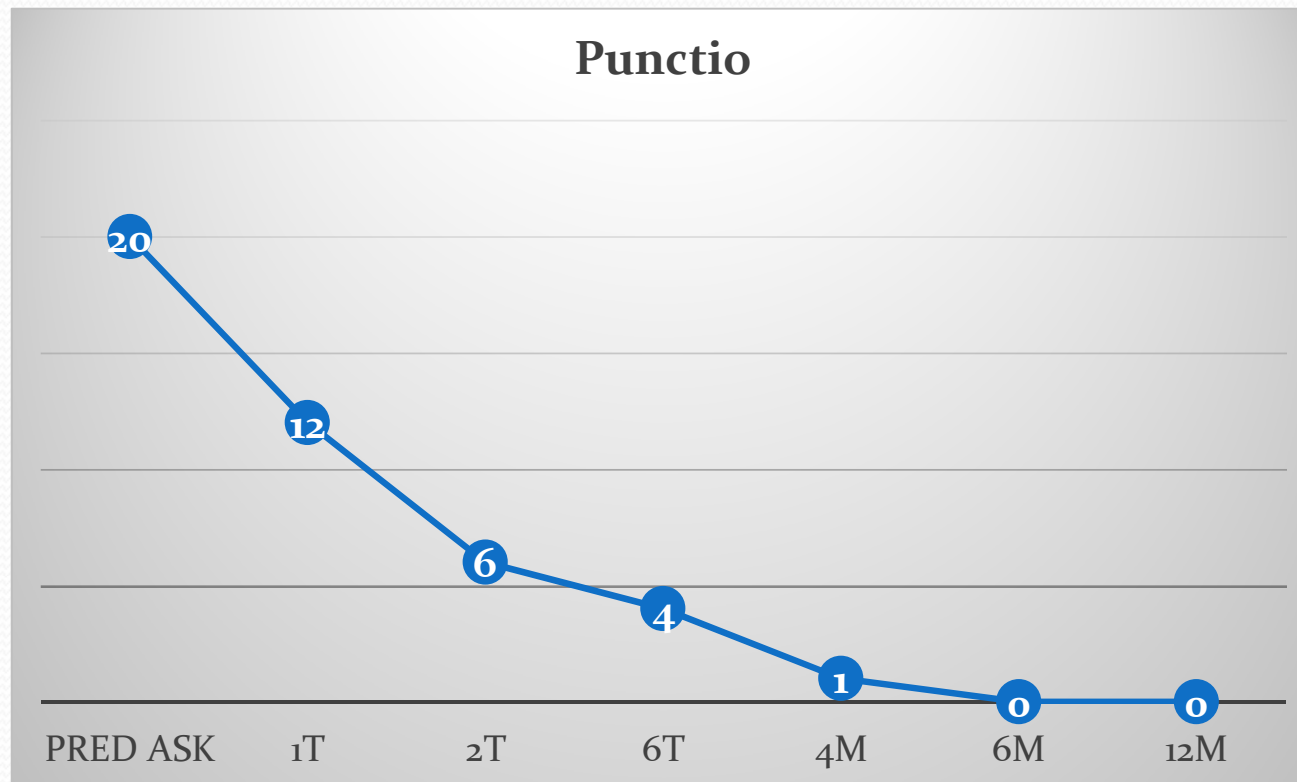
Výsledky

- USG – exsudatívna synovitída s výpotkom (gr 1-4)



Výsledky

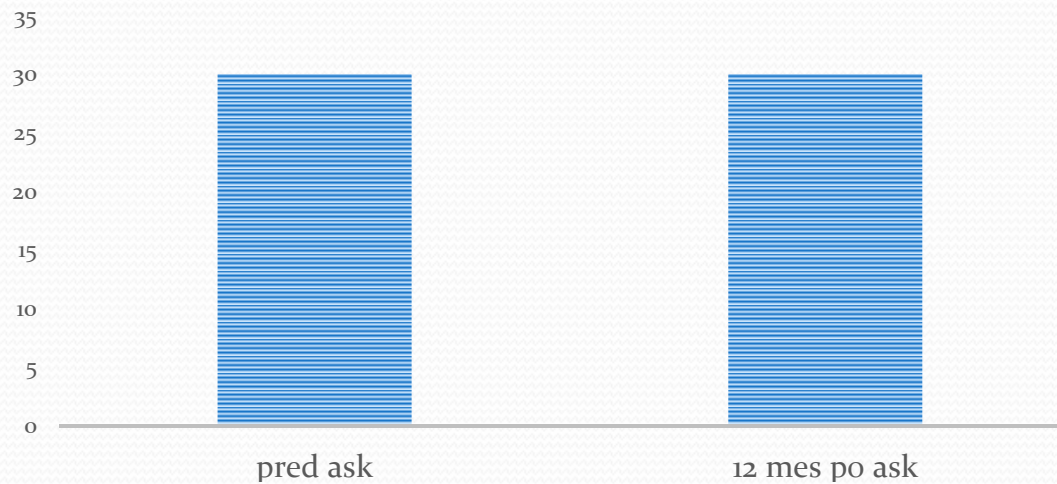
- detritus synovialis
 - pred artroskopiou 40%
 - po artroskopiou nepozorovali



Výsledky

- RTG bez zmeny

KELLGREN- LAWRENCE GR. III



- Korelácia synovitídy (s výpotkom) a bolesťou VAS

Záver

- Artroskopia pri dekompenzovanej artróze 3. stupňa
 - indikovaná ako metóda voľby
 - restitutio ad integrum nie je možné očakávať
 - symptomatická liečba v rozsahu ako sme zistili pri našom sledovaní niektorých vybraných parametrov.
 - zmierneniu klinických a patologicko-fyziologických iritačných príznakov dekompenzovanej gonartrózy - synovitída 1 st bola u 80% pacientov 12 mesiacov od artroskopie
 - stupeň degeneratívnych zmien ostáva nezmenený
 - Potvrdenie korelácie synovitídy s VAS
 - Informovanosť pacienta o limitovaných možnostiach



Ďakujem za pozornosť