

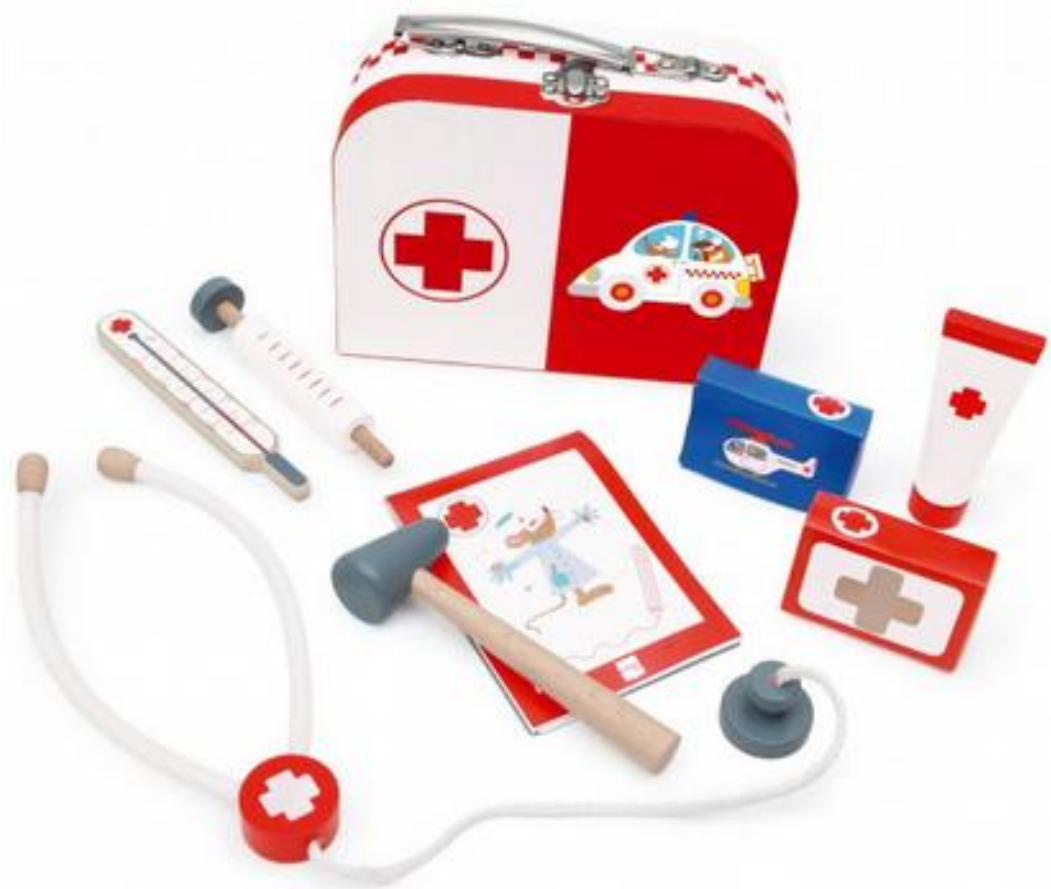Království za žílu aneb jak si poradit v urgentní situaci


Jana Kubalová

Zdravotnická záchranná služba Jihomoravského kraje

Sepse 31. 1. 2020







Potřebujeme intravaskulární vstup?

(X)ABCDE



I. os. zavedení



EUROPEAN
RESUSCITATION
COUNCIL

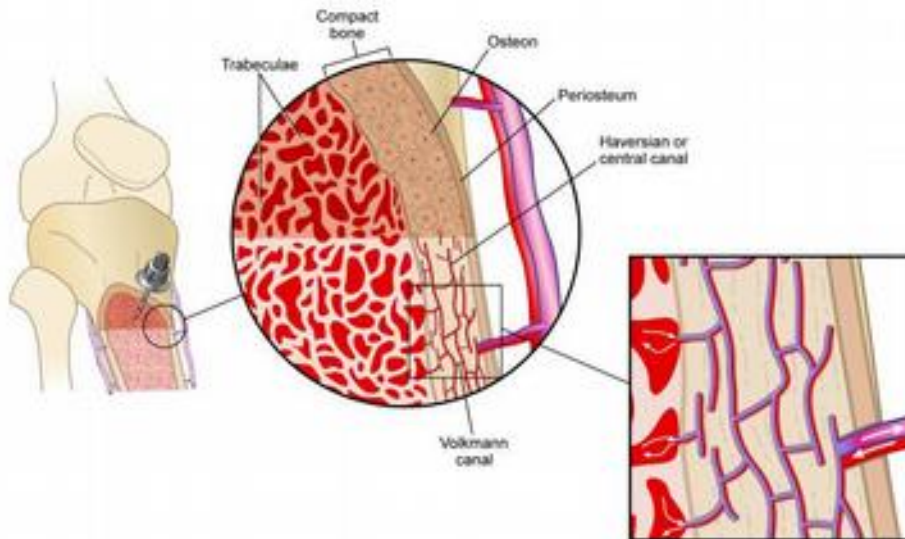


- Děti zástava oběhu nebo dekompenzovaný šok (adrenalin, tekutiny):
i. os = 1. volba (manuál EPALS, CPR GL 2015)

Proč to funguje?



- Ve dřeni hustá síť cév
- Krevní proud rychlý
- Dřeň nezkolabuje
- Léky a tekutiny rychle dosáhnou centrálního cévního řečiště **IO = PIV = efektivní varianta PIV**



Miller, LJ, Kuhn JG, Von Hoff, DD. Does IO equal IV? Prehosp Emerg Care 2005; 9:102

1922 – Drinker et al. – léky a infúze aplikované do kostní dřene (sternum) se rychle vstřebají do centrálního řečiště

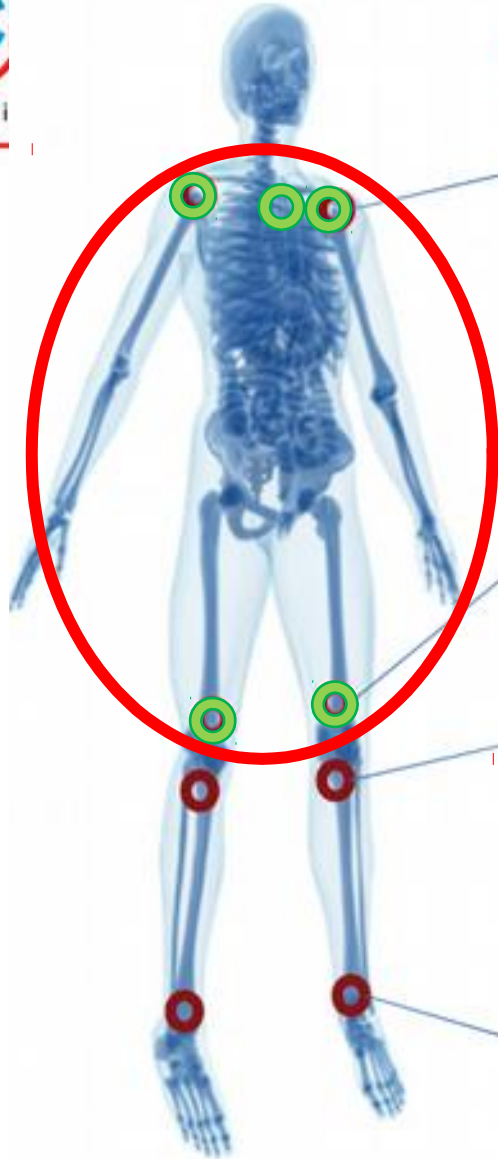
1942 - Papper – doba vstřebání léků do centrálního řečiště je u IV podání a IO identická



... 0 11

Místa zavedení

4 Sites, 8 Targets



Proximal Humerus

Preferred site for adults
Optimal site for high flow and quick drug uptake
Awake, responsive patients
Less painful

Distal Femur

Best under 12 years

Proximal Tibia

Unresponsive
Unfamiliarity with other sites
Unable to landmark other sites

Distal Tibia

Larger patient
Unable to access other sites

Site selection

Dependent upon:

- No previous IO in 48 hours
- Absence of contraindications
- Accessibility
- Ability to secure & monitor

Semi-automatické Arrow EZ-IO™ - EZ (Easy) IO (IntraOsseal) access



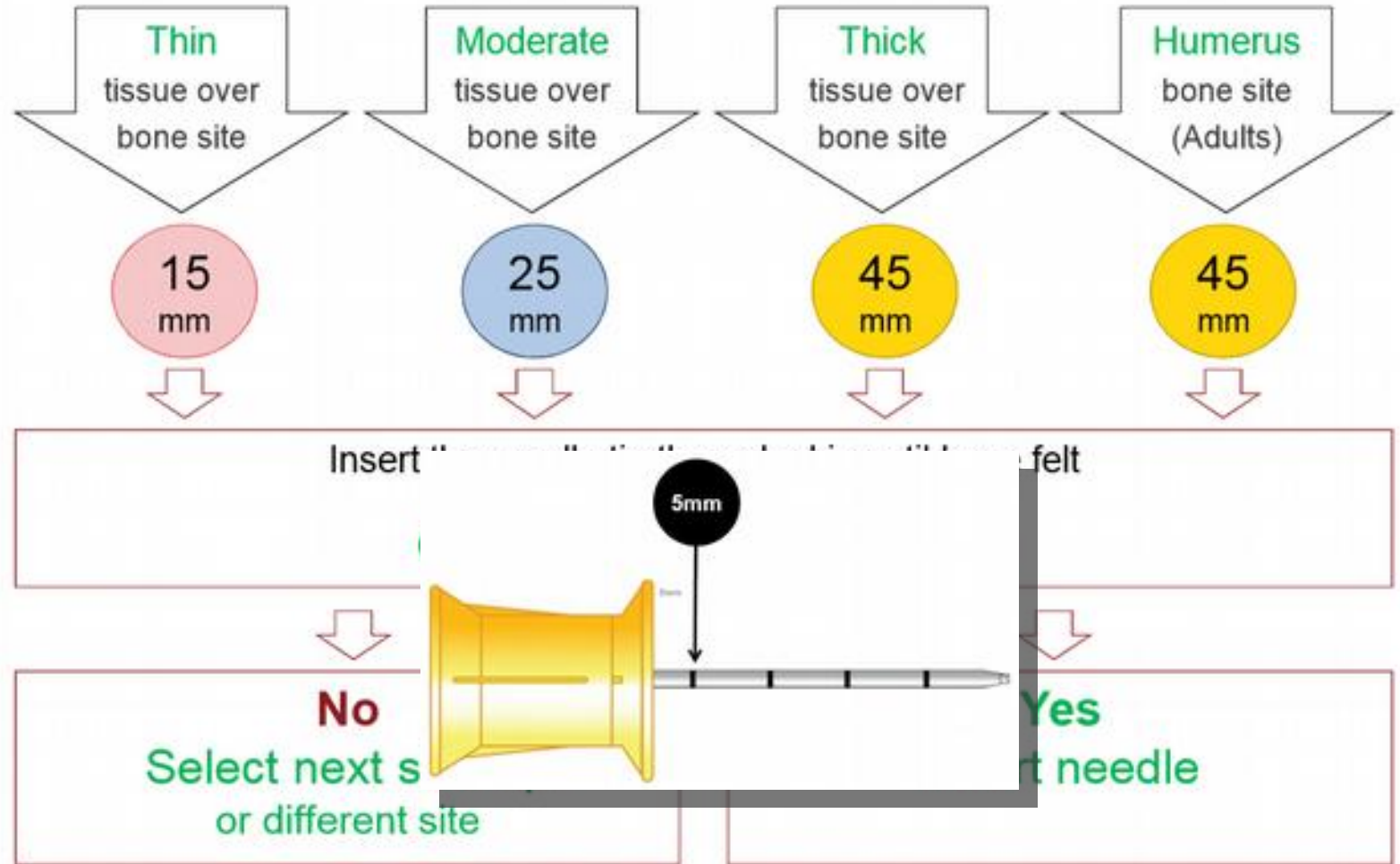
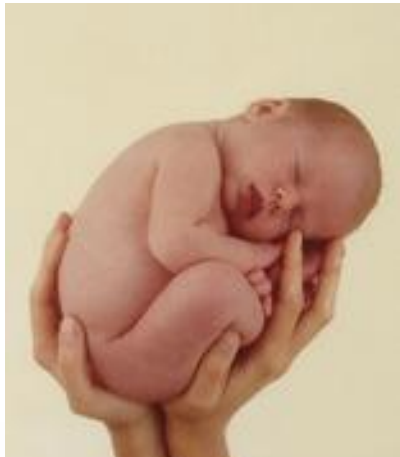- Rychlejší zavedení
- Vysoké procento úspěšnosti
- Minimální riziko komplikací
- Lepší, než manuální a jiné semi-automatické pomůcky

Efficacy and safety of the EZ-IO™ intraosseous device: Out-of-hospital implementation of a management algorithm for difficult vascular access^{☆,☆☆}

Nicolas Gazin^a, Harold Auger^a, Patricia Jabre^{a,b,c}, Christine Jaulin^a, Eric Lecarpentier^a, Catherine Bertrand^a, Alain Margenet^a, Xavier Combes^{a,*}

Weiser G et al, Current advances in intraosseous infusion - a systematic review, Resuscitation, 2012 Jan;83(1):20-6. doi: 10.1016/j.resuscitation.2011.07.020. Epub 2011 Aug 24. (179 => 10)

Klause A, Williams B., Intraosseous access in the prehospital setting: literature review. Prehosp Disaster Med. 2012 Oct;27(5):468-72. doi: 10.1017/S1049023X12001124. Epub 2012 Aug 9. (2100 => 20)



Mýty? Fakta?

- CVK je zavedený stejně rychle?
- Průtok je pomalý?
- Riziko vážných komplikací?
- Poškození růstové ploténky?



Patient Safety in Surgery

Research

Is the intraosseous access route fast and efficacious compared to conventional central venous catheterization in adult patient resuscitation in the emergency department? A prospective observational pilot study

Bernd A Leidel^{1,3}, Chlodwig Kirchhoff², Viktoria Bogner², Julia Stöckl², Wolf Mutschler², Karl-Georg Kanz² and Volker Braunstein²

Address: ¹Department of Emergency Medicine, Charité - University Medicine Berlin, Campus Benjamin Franklin, Hindenburgstr. 30, 10243 Berlin, Germany, ²Department of Trauma, University Medical Centre of Munich, Downtown, Nussbaum Street 20, 80336 Munich, Germany, ³Helicopter Emergency Medical Service Christoph 31, ADAC Luftrettung air rescue services, Charité - University Medicine Berlin, Campus Benjamin Franklin, Hindenburgdamm 30, 12203 Berlin, Germany

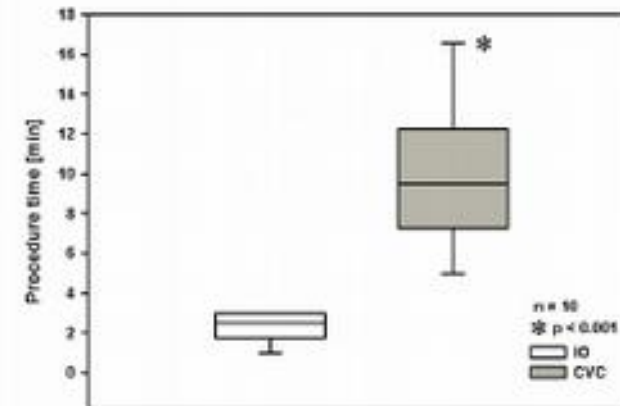


Figure 3
Procedure time of intraosseous (IO) cannulation was significantly shorter than central venous catheterization (CVC) for vascular access to enable drug and fluid administration in adult emergency patients under resuscitation.

jugular or subclavian veins. The success rate on first attempt was 90% for IO insertion versus 60% for CVC. Mean procedure time was significantly lower for IO cannulation (2.3 min ± 0.8) compared to CVC (9.9 min ± 3.7) (p < 0.001). As for complications, failure of IO access was observed in one patient, while two or more attempts of CVC were necessary in four patients. No other relevant

impossible peripheral IV access. Furthermore, IO cannulation requires significantly less time to enable administration of drugs or infusion solutions compared to CVC. Because CVC was slower

Dolister M et al, Intraosseous vascular access is safe, effective and costs less than central venous catheters for patients in the hospital setting, J Vasc Access 2013; 14(3): 216 – 224

„Results:

- 105 cases, six centers
- 94% of placements were successful on the first attempt
- mean time to IO access was 103.6 ± 96.2 seconds
- one serious complication – a lower extremity compartment syndrome
- IO access costs \$100/patient.

Conclusions:

- IO catheter placement than reported for CVCs, few complications and high user satisfaction

- Hagen-Poiseuilleův zákon: $Q = \pi r^4 \cdot \Delta P / 8 \mu l$
 - Q = průtok
 - r = poloměr kanyly
 - ΔP = tlakový gradient mezi začátkem a koncem
 - M = viskozita podávaného roztoku
 - l = délka kanyly

⇒ průtok závisí přímo úměrně na čtvrté mocnině poloměru

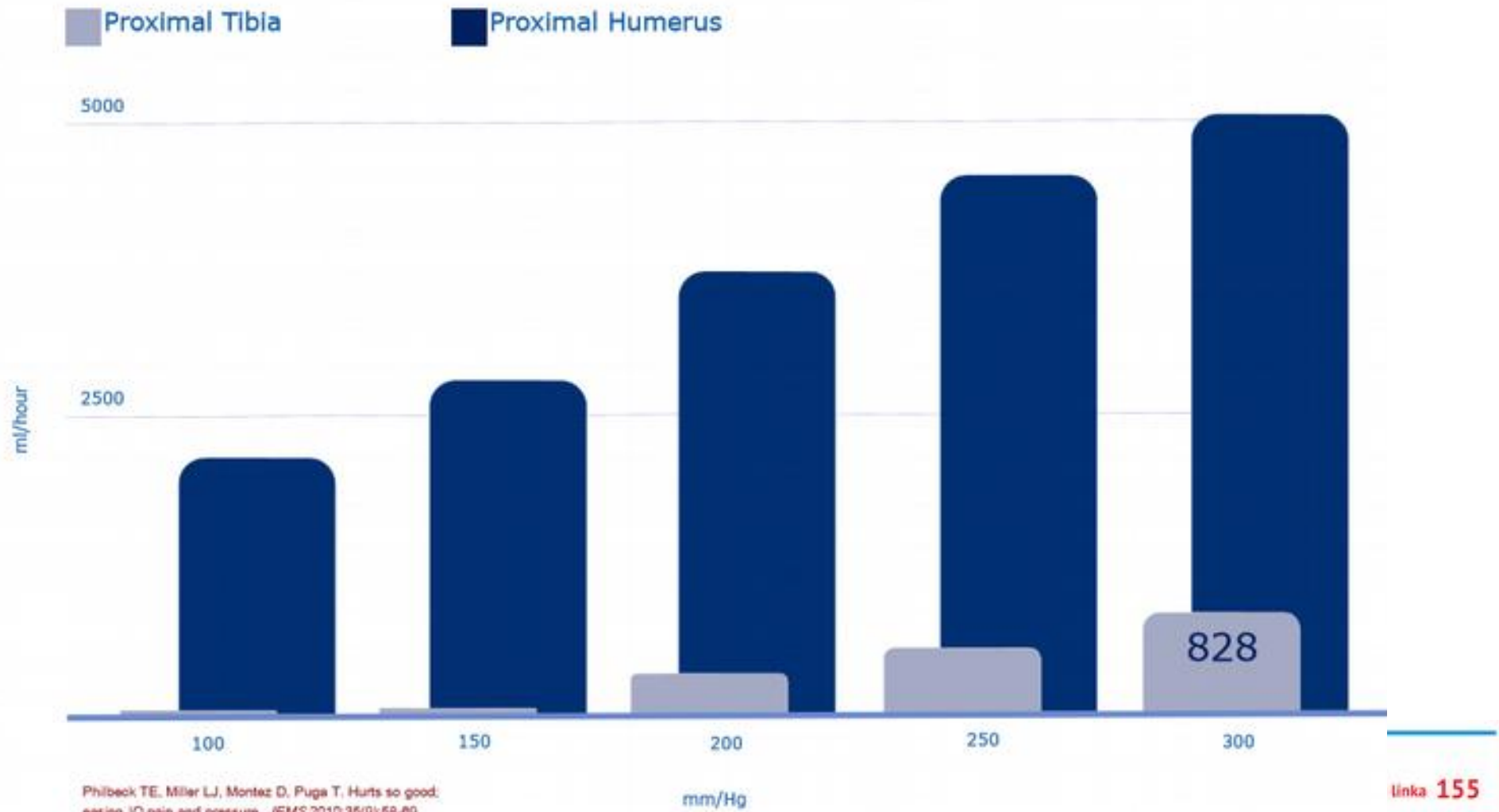
⇒ průtok krátkou kanylou zavedenou do PŽ ($l=4,5\text{cm}$) bude min. $3x \uparrow$ než průtok katétrem téhož kalibru zavedeném do CŽ ($l=15 - 20\text{cm}$)

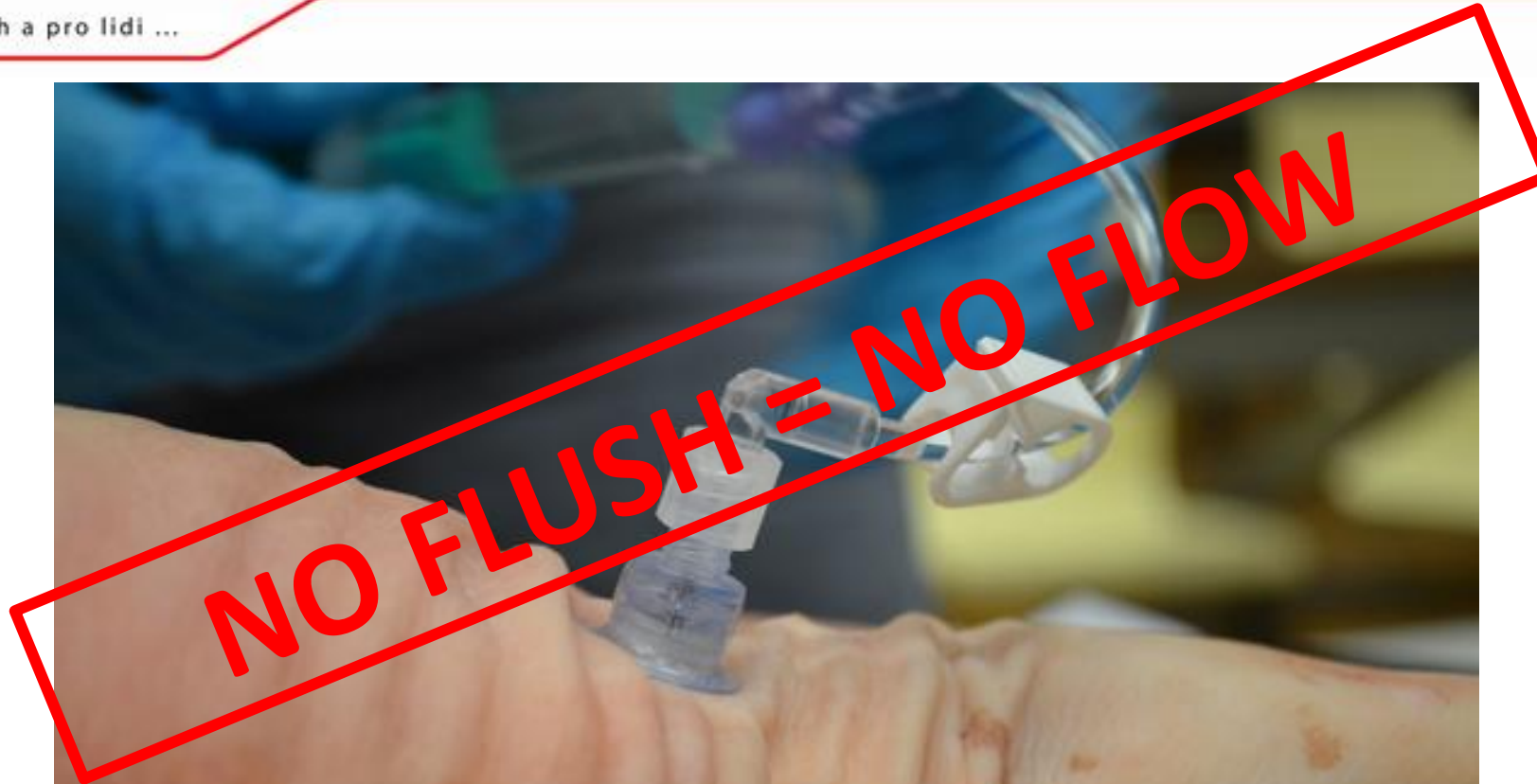⇒ video



MC-001297 Proximal Humerus Subclavian Vein Dissected and Flush (Cadaveri....mov)

Průtok v závislosti na přetlaku

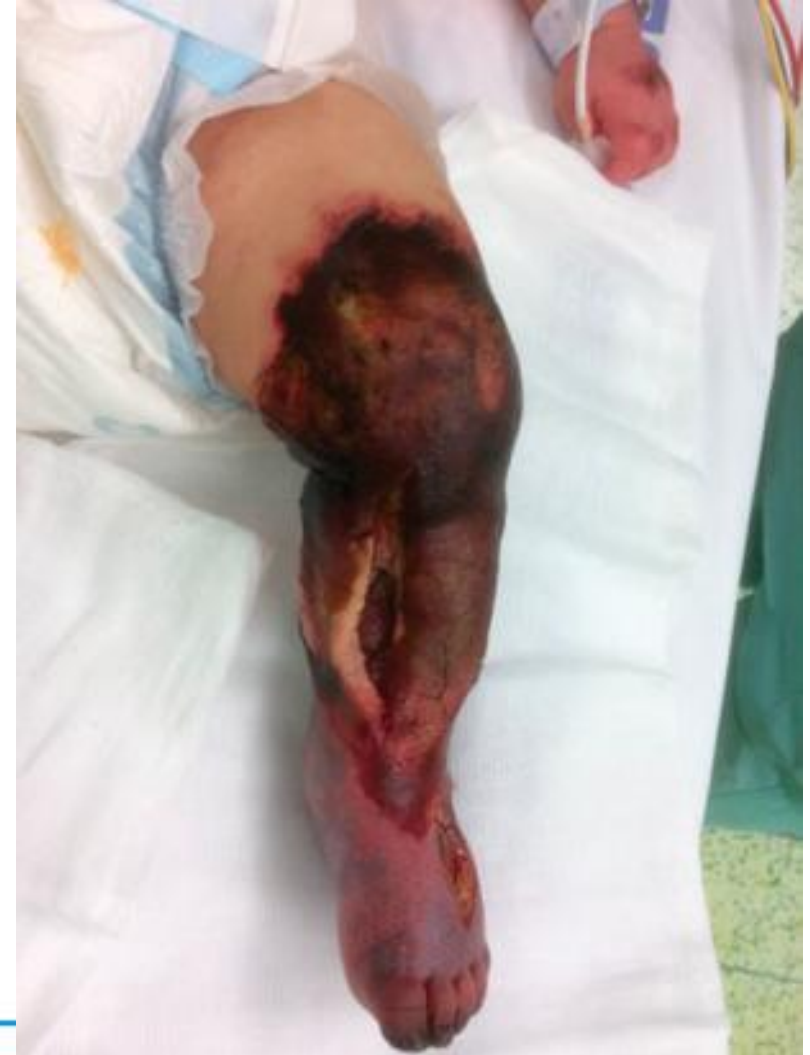



ASPIROVAT, APLIKOVAT BOLUS!!!
(během 5 s 5 - 10 ml FR, děti 2 – 5 ml)

Máme se bát komplikací?

- Možné závažné komplikace IO:
osteomyelitis, fraktura, infekce,
extravazace, kompartment syndrom
a poranění růstové ploténky, tuková
embolie





Serious Complications of Intraosseous Access during Infant Resuscitation

Jiri Molacek¹ Karel Houdek¹ Václav Opatrný¹ Jiri Fremuth² Lumir Sasek² Inka Treskova³
Vladislav Treska¹

¹Department of Vascular Surgery, University Hospital in Pilsen, Pilsen, Czech Republic

²Department of Pediatric Intensive Care Unit, University Hospital in Pilsen, Pilsen, Czech Republic

³Department of Plastic Surgery, University Hospital in Pilsen, Pilsen, Czech Republic

[Address for correspondence](#) Jiri Molacek, MD, PhD, Department of Vascular Surgery, University Hospital in Pilsen, alej Svobody, Pilsen 30460, Czech Republic (e-mail: molacek@fnplzen.cz).

Eur J Pediatr Surg Rep 2018;6:e59–e62.

We report on a 2.5-month-old infant with ischemia of the left leg and compartment following intraosseous needle application during resuscitation. Unfortunately, this event led to major limb amputation. The cause, mechanism, and prevention of this severe complication are discussed in this article.

Komplikace- statistiky

- Děti – osteomyelitis < 0, 6% (4200 pacientů, komplikace = bakteriémie v době vpichu, prodloužená doba inserce)

Rossetti, VA, Thompson, BM, Miller, J et al. Intraosseus infusion: an alternative route of pediatric access. Ann Emerg Med 1985; 14:885-8

- Na histopat. změny ve dřeni po IO inf. nemá vliv ani rychlost ani osmolalita (u prasat)

Brickman KR, Rega P, Schoolfield L, Harkins K, Weisbrode SE, Reynolds G: Investigation of bone developmental and histopathologic changes from intraosseous infusion. Ann Emerg Med October 1996;28:430-435

Complication with Intraosseous Access: Scandinavian Users' Experience

Peter Hallas, MD,* Mikkel Brabrand, MD,† and Lars Folkestad, MD‡

Complication with Intraosseous Access

Hallas et al

Table. Complication rate with intraosseous access (IO) reported by Scandinavian users - listed by device.

IO-equipment used	All	%	EZ-IO	B.I.G	Cook	Others	p-value*
Cases reported	1,802	100.0	861	255	418	268	
Start complications							
Equipment difficult to assemble	36	2.0	4	21	5	6	< 0.0001
Difficult to identify correct anatomical site	57	3.2	28	17	5	7	0.0013
Bended or broken needle	72	4.0	11	17	20	24	< 0.0001
Patient discomfort / pain	128	7.1	73	13	20	22	0.0663
Difficult to penetrate the periosteum	186	10.3	18	56	51	61	< 0.0001
Difficult to aspirate bone marrow	221	12.3	92	51	38	40	< 0.0001
Complications in use							
Difficult to inject fluid and drugs	133	7.4	59	33	27	14	0.0026
Slow infusion despite use of pressure bag	159	8.8	77	32	34	16	0.0610
Displacement after insertion	153	8.5	47	50	38	18	< 0.0001
Extravasation	66	3.7	25	12	17	12	0.4089
Late complications							
Compartment syndrome	10	0.6	6	1	1	2	0.796
Osteomyelitis	7	0.4	4	1	1	1	1.000
Skin infection	6	0.3	4	1	1	0	0.829

Poranění růstové ploténky?

- Žádné abnormality na růstové ploténce při klinickém i rtg vyšetření u 3. – 4. týdenních prasat (FR, NaHCO₃)

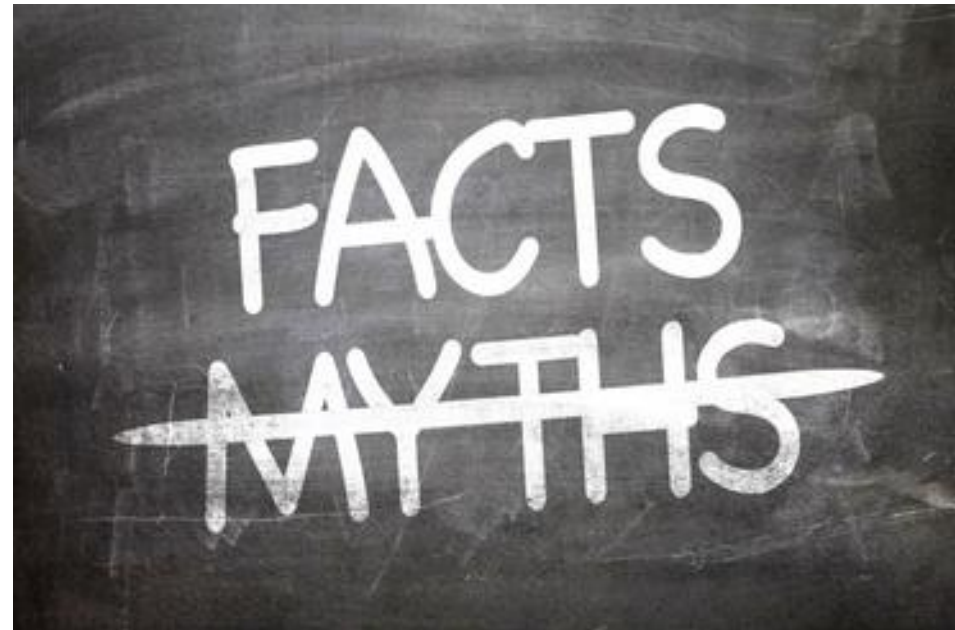
Brickman KR, Rega P, Koltz M, Guinness M. Analysis of growth plate abnormalities following intraosseous infusion through the proximal tibial epiphysis in pigs. Ann Emerg Med. 1988 Feb. 17(2):121-3.

- 23 dětí, prox. tibie, prům. věk 18.6m, zavedení 5 hodin, objem 225 ml, rtg vyš. za 29,2 m, porovnání obou končetin, žádné signifikantní změny mezi punktovanou a kontrolní končetinou

Claudet I., Baunin C., Laporte-Turpin E., Marcoux MO, Grouteau E., Cahuzac JP: Long-term effects on tibial growth after intraosseous infusion: a prospective, radiographic analysis. Ped. Emerg. Care. 2003 Dec;19(6):397-401.

Mýty

- ~~CVK je zavedený stejně rychle~~
- ~~Průtok je pomalý~~
- ~~Riziko komplikací~~
- ~~Poškození růstové ploténky~~



Správné provedení

- Správné místo, správná technika, správná délka jehly, častá kontrola – eliminace komplikací



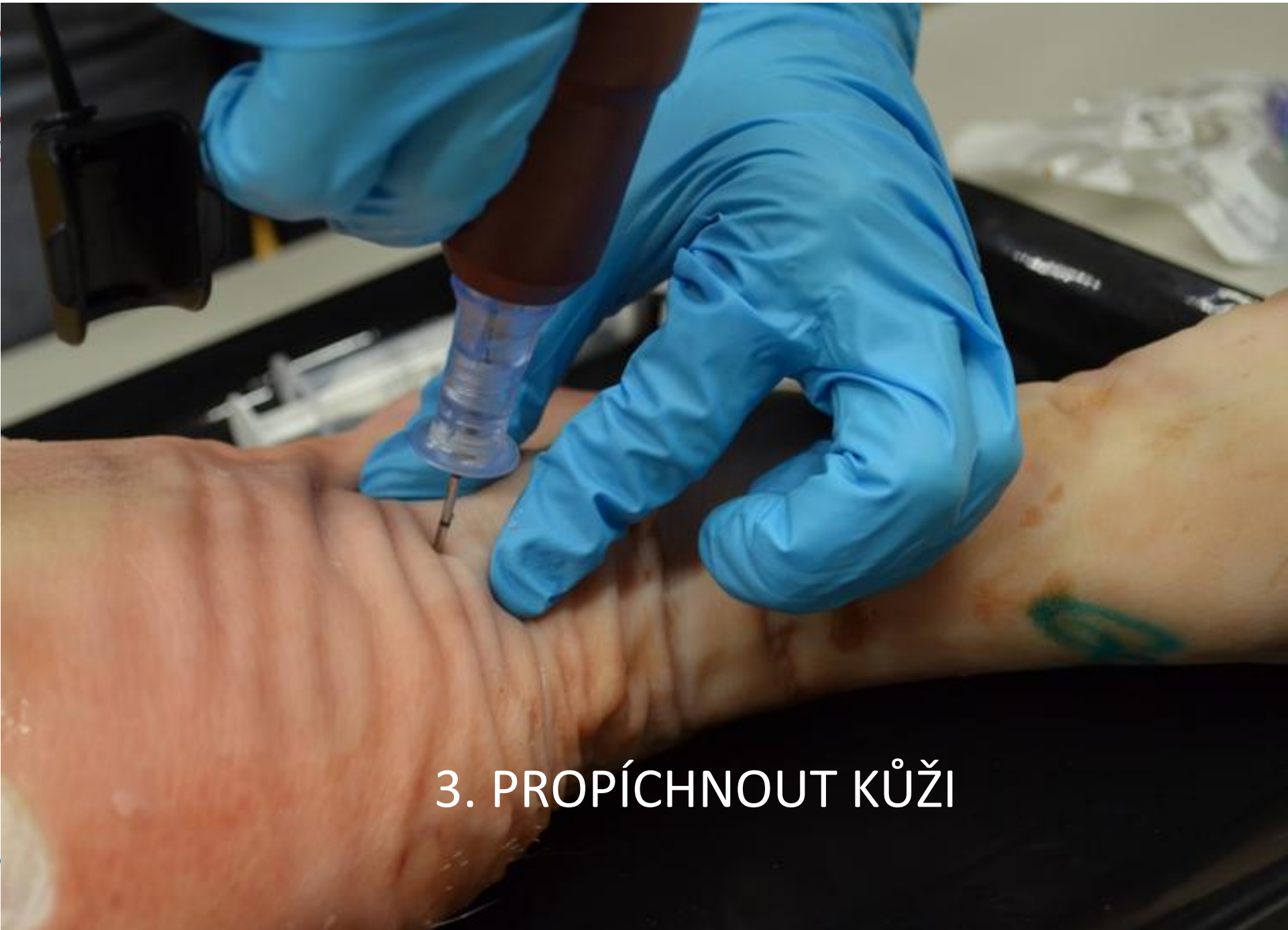1. VYHLEDAT MÍSTO VPICHU

- Dle situace
- Dle věku
- Dle dostupného zařízení
- EZ-IO zvolit správnou délku jehly

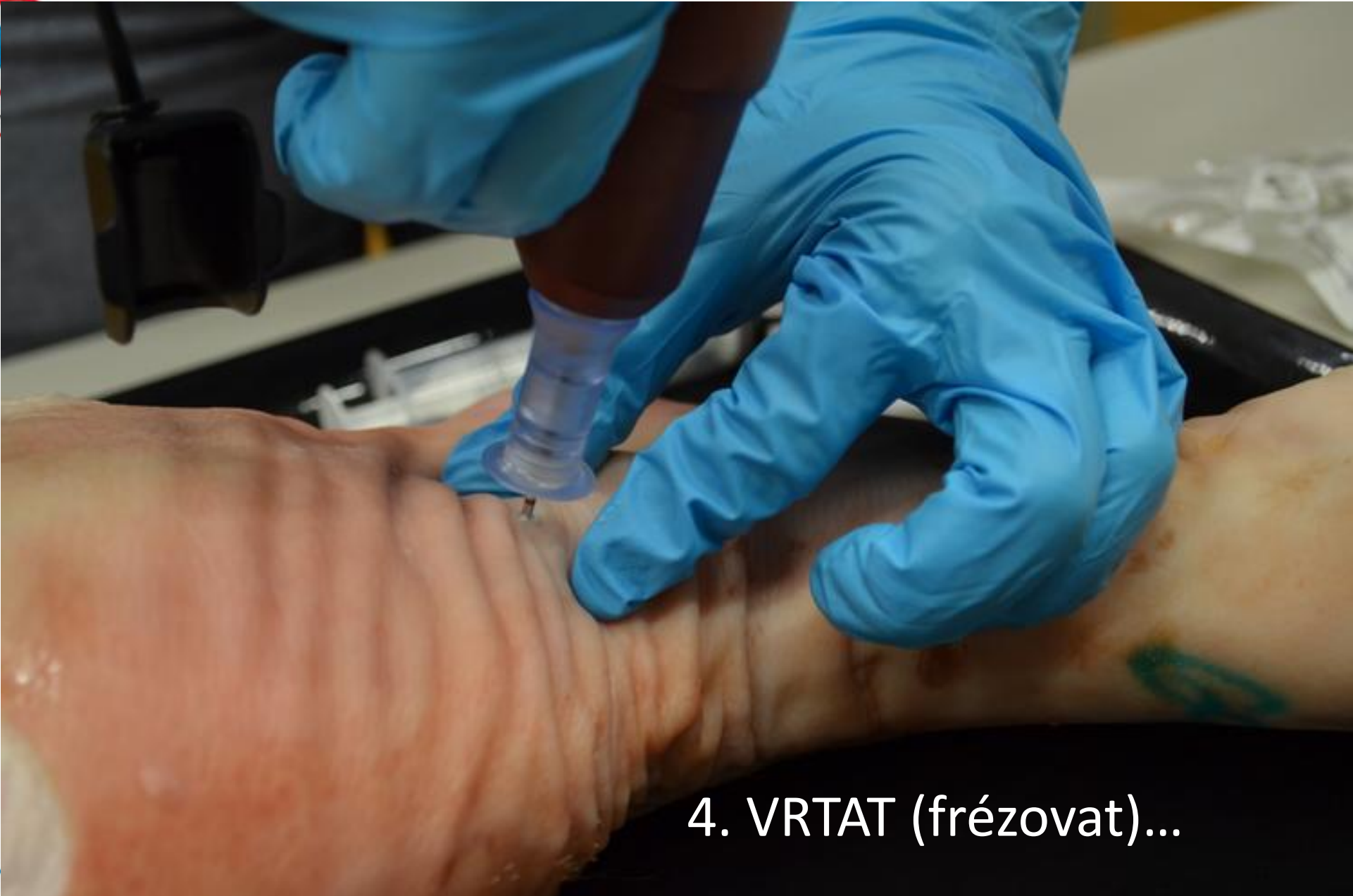

2. PŘÍPRAVA MÍSTA VPICHU

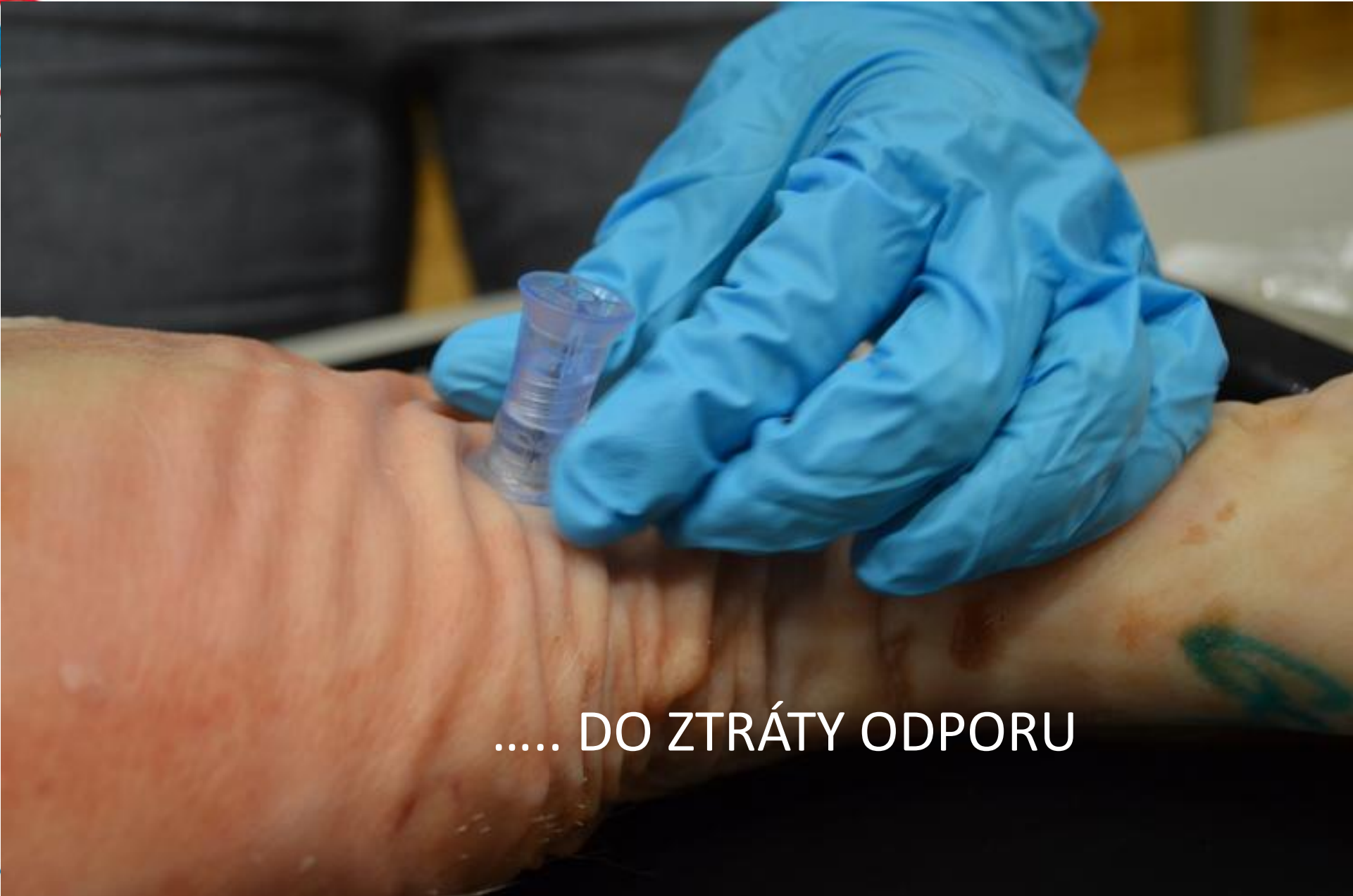- Dezinfekce
- Asepse



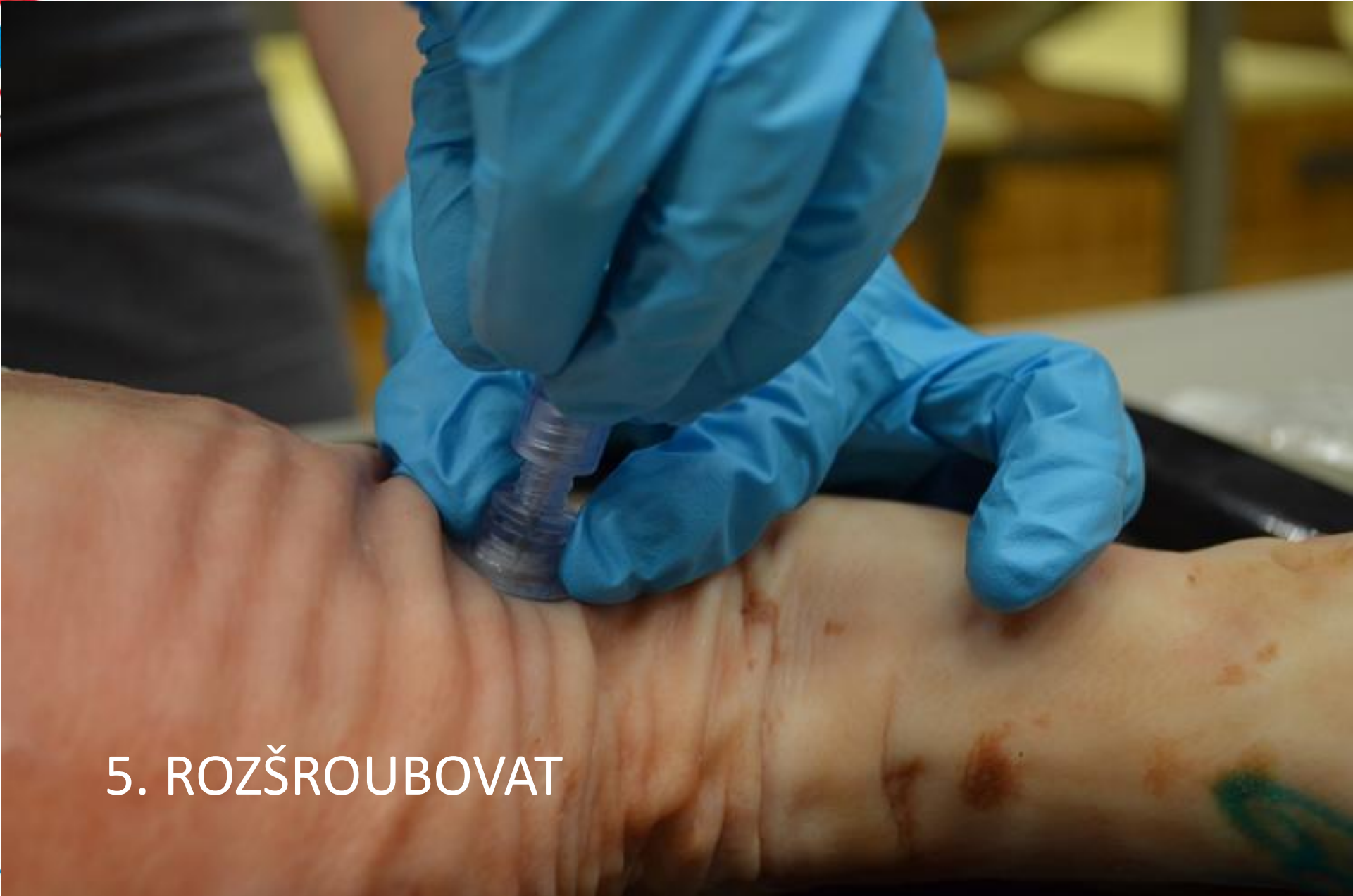
3. PROPÍCHNOUT KŮŽI



4. VRTAT (frézovat)...



..... DO ZTRÁTY ODPORU

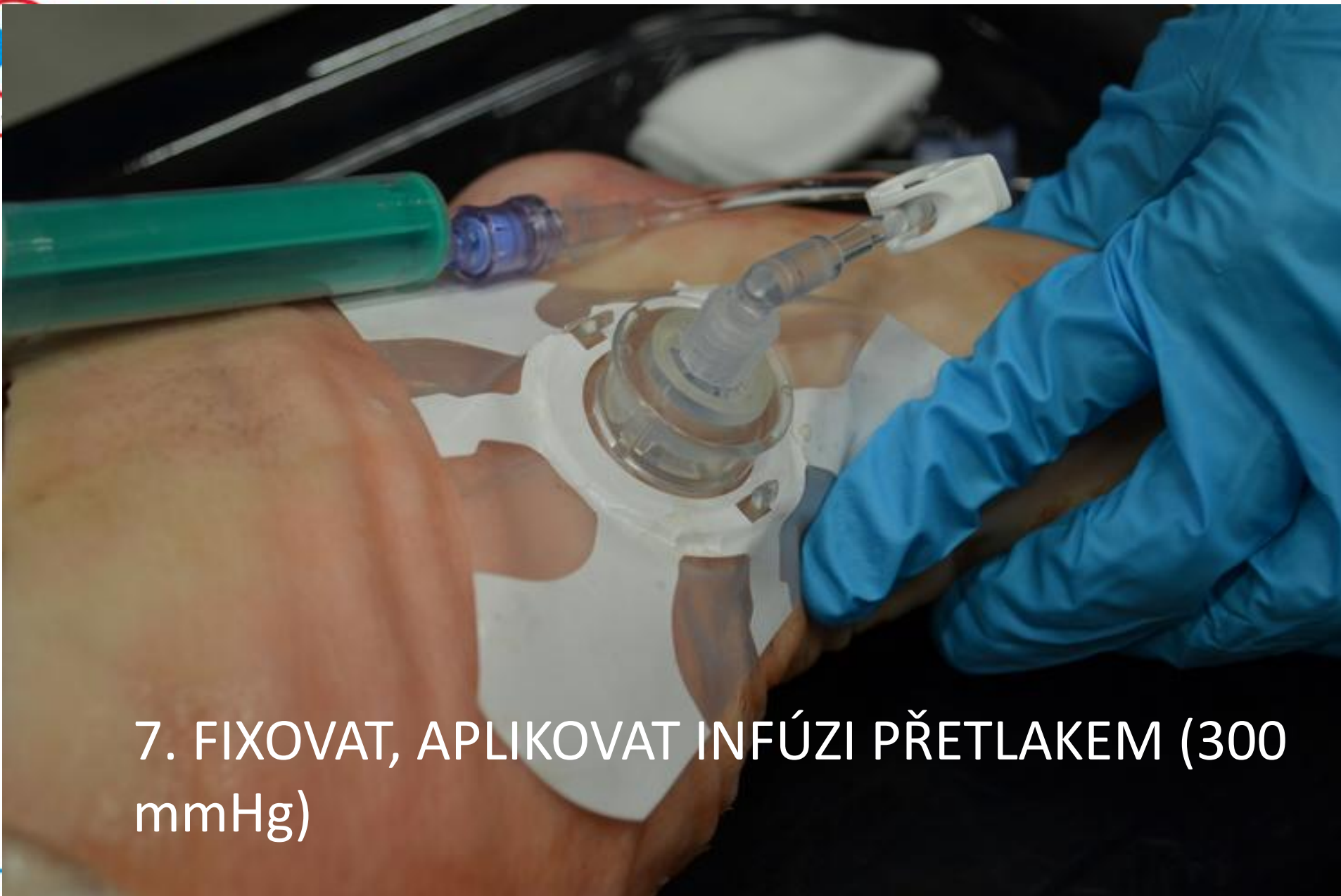


5. ROZŠROUBOVAT



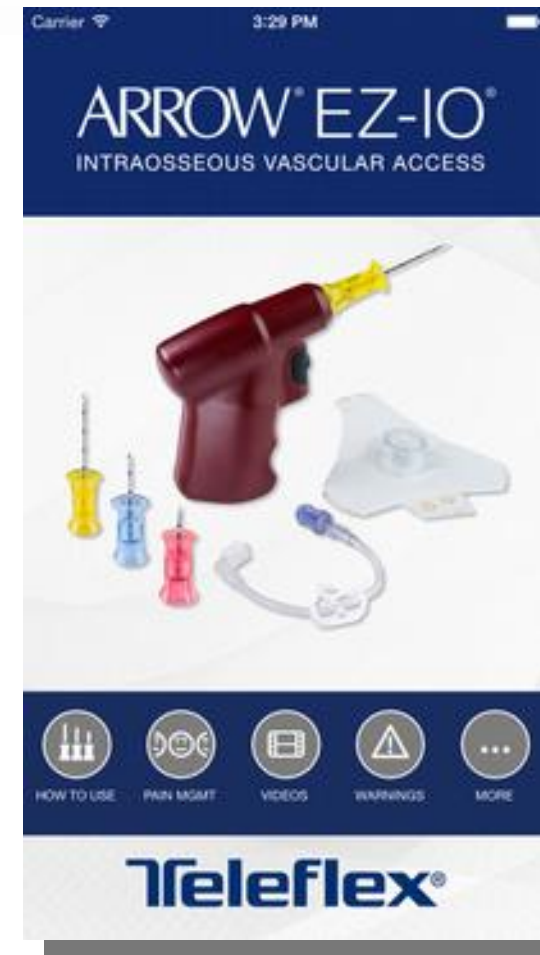NO FLUSH = NO FLOW

6. ASPIROVAT, APLIKOVAT BOLUS!!! (během
5 s 5 - 10 ml FR, děti 2 – 5 ml)



7. FIXOVAT, APLIKOVAT INFÚZI PŘETLAKEM (300 mmHg)

**THANK YOU
FOR YOUR ATTENTION**



MUDr. Jana Kubalová
Zdravotnická záchranná služba Jihomoravského kraje, p.o.
kubalovaj@zsjmk.cz

